

# Neurobiology and Neuropsychology of White Matter Disease

CHARLES J. VELLA, PHD

SEPTEMBER 7, 2016

Thanks to C. Filley, Eric Neuman & C. Armstrong

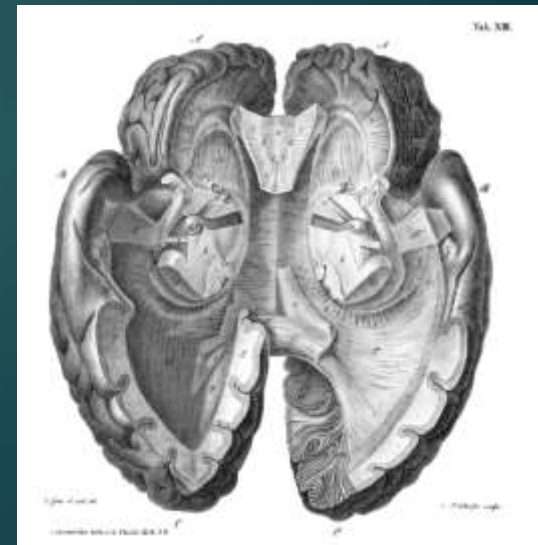
# White matter history

- ▶ Rene Descartes (1596-1650)
  - ▶ reflex
  - ▶ nerves are little tubes (reference to white matter)
  - ▶ animal spirits
  - ▶ “filaments” in nerves
  - ▶ pineal gland controls flow of animal spirits
- ▶ Anatomist Galen often credited with animal spirits concept



## History 2

- ▶ Andreas Vesalius (d. 1564): first anatomical identification of white matter as neuroanatomical structure
- ▶ Techniques: 1664: boiling in water - white matter “fibers” 1684: boiling in oil - fasciculi
- ▶ Thomas Willis (1675): white matter as elaboration of sensory signals into perception, idea of connectivity
- ▶ Emmanuel Swedenborg (1772): descent through brain stem and spinal cord
- ▶ 1809: fixing (alcohol & ammonia) & gross dissection



# History 3

- ▶ Phrenologists Franz Gall (1828) and Johann Spurzheim (1832) correctly describe White matter consists of individual fibers and tracts that connect various regions
- ▶ 1872, 1885 Meynert: elaborated on white matter systems
  1. association systems: arcuate and long fibers that facilitate cortico-cortical communication
  2. commissural pathways linking two hemispheres
  3. afferent (to) & efferent (away) projection systems between cortex and subcortical structures, cerebello-cortical afferents

# History 4

- ▶ Theodor Schwann (1882): insulating sheath on axon in 1838
- ▶ Rudolph Virchow (1902): use of word “myelin”
- ▶ Paul Flechsig (1929):
  - ▶ white matter tracts (pyramidal, internal capsule, auditory radiation)
  - ▶ myelinogenesis (neuron maturity only when myelinated);
  - ▶ rule that sensory areas only connect through association areas

## History 5: WM Syndromes

- ▶ Jean Charcot (1893): description of Multiple Sclerosis
- ▶ Jules Dejerine (1917): role of Corpus Callosal splenium in pure alexia
- ▶ Binswanger: description of small vessel white matter disease (now UBOs)
- ▶ Hugo Liepmann (1925): anterior CC in unilateral apraxia

## History 6: WM in dementia

- ▶ Von Stockert (1932): coined term “subcortical dementia” in postencephalitic patients
- ▶ Martin Albert (1974): subcortical dementia in progressive supranuclear palsy (PSP)
- ▶ McHugh & Folstein (1975): subcortical dementia in Huntington’s disease
- ▶ Stephen Rao (1986): neurobiology of Multiple Sclerosis
- ▶ Navia (1986): AIDS subcortical dementia

# History 7

- ▶ Norman Geschwind (1965): disconnection syndrome theory: lesions of association cortex or white matter tracts
- ▶ Roger Sperry and Michael Gazzaniga: corpus callosum resection: split brain
- ▶ Hachinski (1987) leukoaraiosis (“normal” vascular white matter changes in elderly)

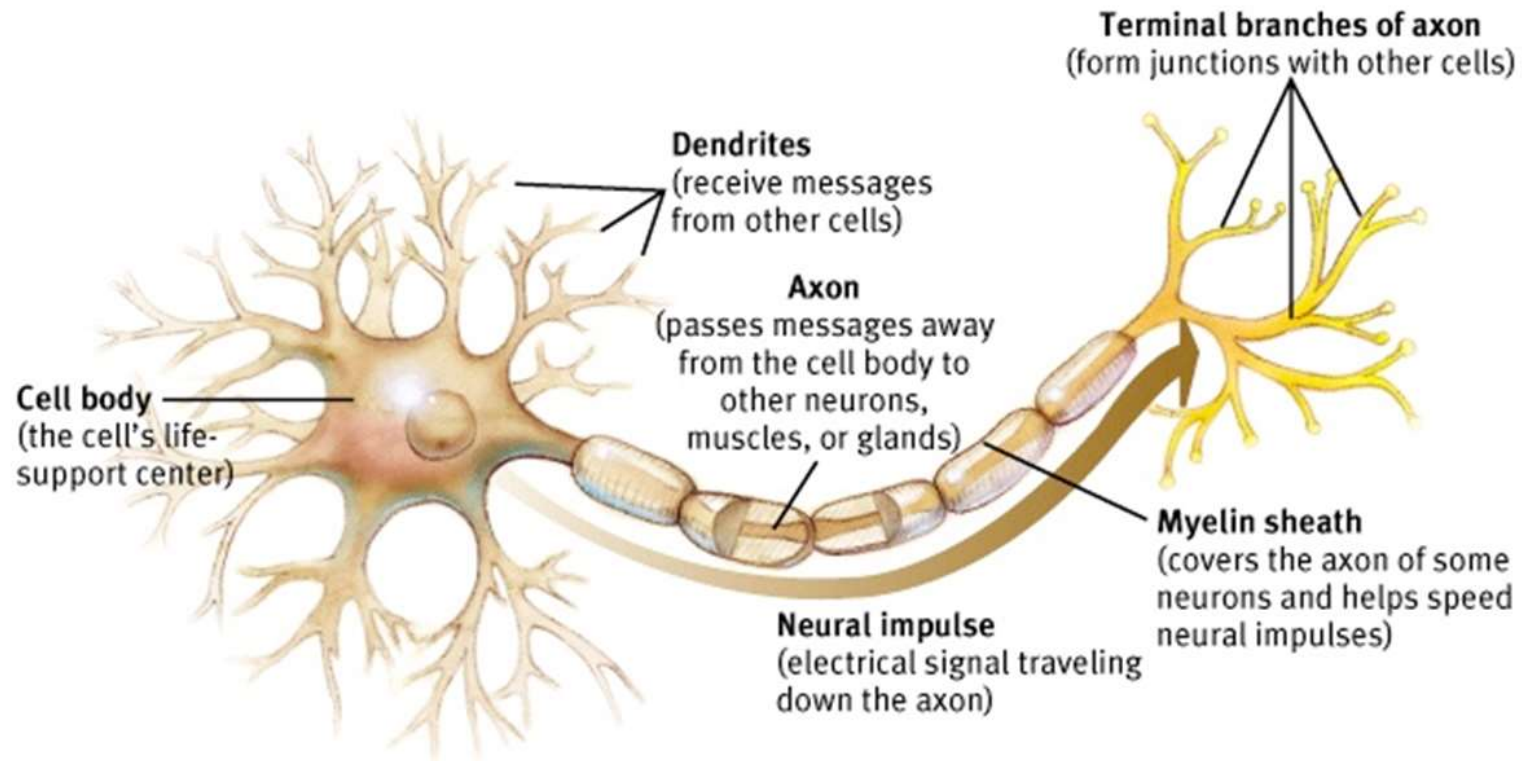


## History 8

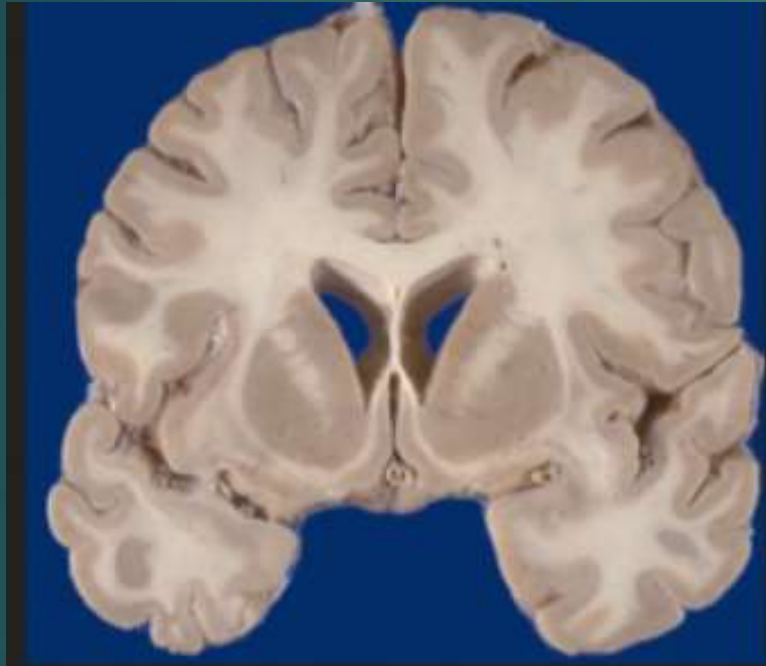
- ▶ Christopher Filley (1988): White matter dementia; author of *The Behavioral Neurology of White Matter*
- ▶ Rourke (1995): Nonverbal Learning Disorder from white matter dysfunction
- ▶ Carol Armstrong (2004): Cognition and White Matter

# Neuron

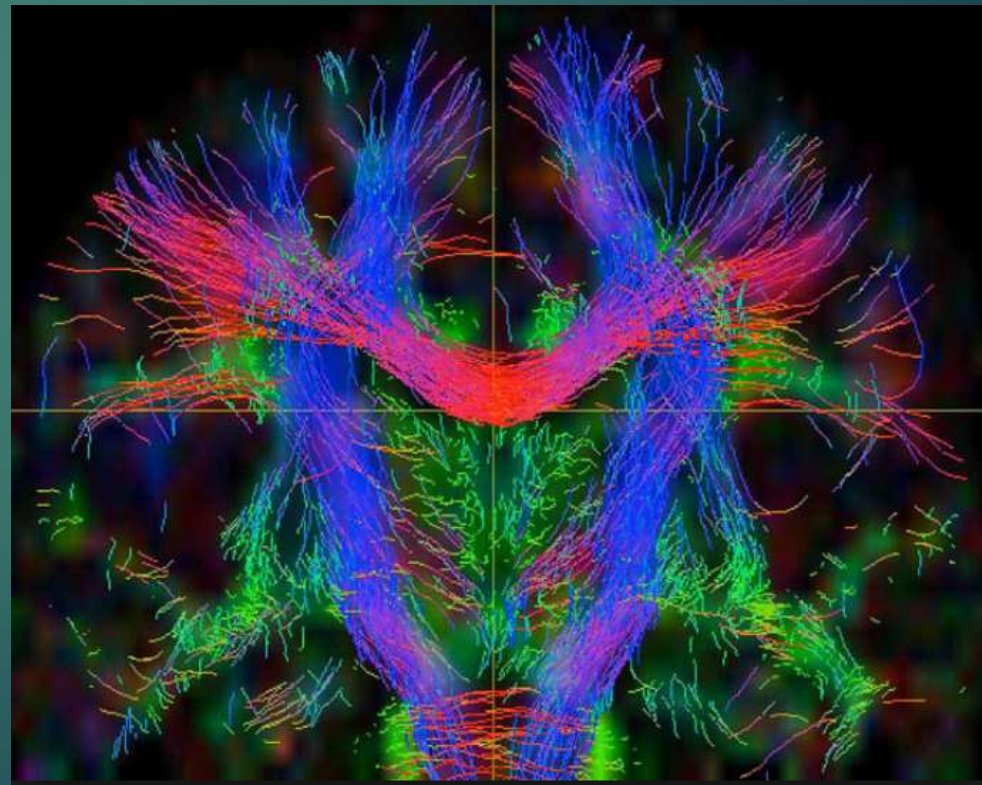
## Neuronal Structure



# White Matter: Insulation on your neuronal axons



The Internet of your brain:  
How fast you process information

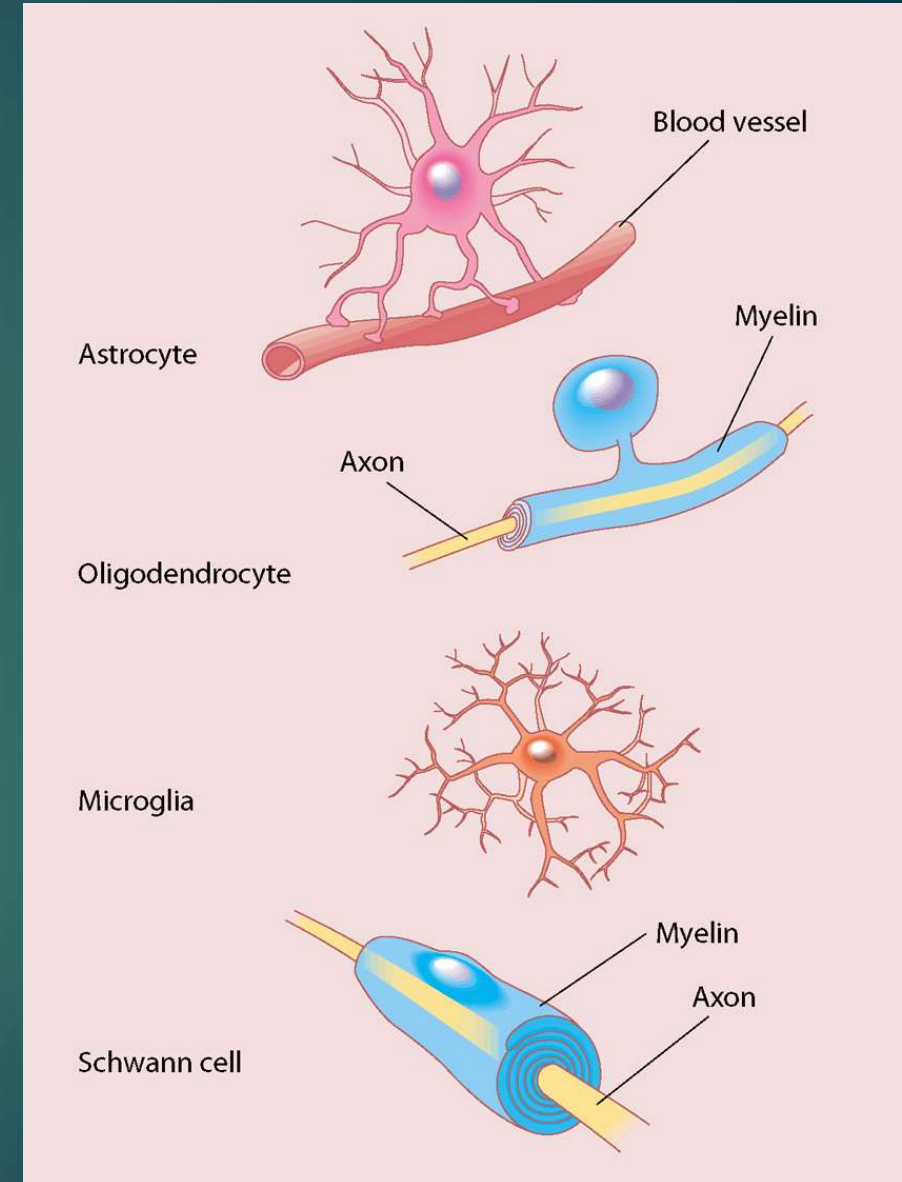


# Anatomy: Glial cells as important as Neurons

- ▶ White Matter: 40% of cross-sectional area of brain and 50% of volume, myelination of axons by glial cells
- ▶ Myelin: Greek (myelos) for marrow, lipid rich (70%): insulation of axons, effects electrical properties of axon; composed of 30% protein, 40% cholesterol
- ▶ Glial Cells: oligodendrocytes and astrocytes;
  - ▶ Oligodendrocytes form myelin in CNS
  - ▶ Schwann cells form it in PNS
- ▶ WM does not have neuronal cell bodies, dendrites, or synapses
- ▶ Neurons don't work or learn correctly if glial cells impaired:  $84.6 \pm 9.8$  billion glial cells.

# Glia (Glue)

- ▶ Support staff of neurons (named for the Greek term for “glue”)
- ▶ Neuronal maintenance: feed, insulate (Myelin sheath), attack invaders
- ▶ Form blood-brain barrier
- ▶ Removing debris and excess neurochemicals
- ▶ Structural support for neurons
- ▶ Critical role in brain development
- ▶ Enhances neuronal performance: overall moderator, regulating which messages are sent on and when; speeding or slowing the electrical signals and strengthening neuron-to-neuron connections.





# New roles for glia

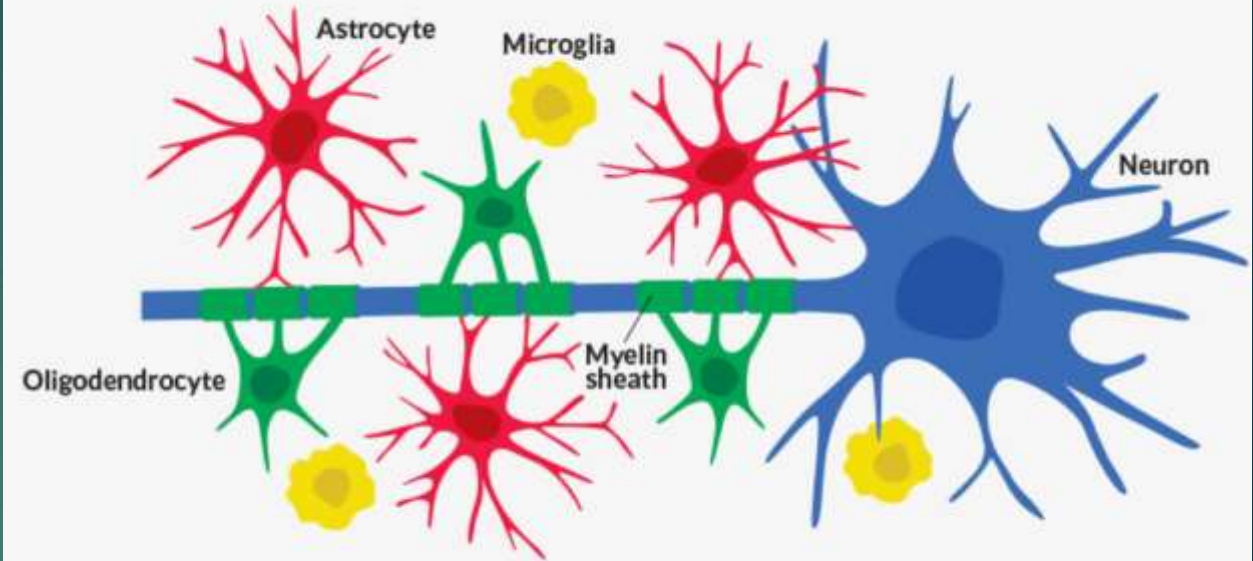
3 types of glia: microglia, astrocytes and oligodendrocytes.

Tiny microglia puff up and kill invaders, using chemical warfare to kill infiltrators, while devouring dead and dying cells. Microglia also prune and clear away unnecessary nerve cell connections.

Astrocytes nestle some of their pointed projections against synapses, playing a role in how neurons make connections. Other astrocyte projections connect to nearby capillaries, helping to bring oxygen-rich blood to the neurons.

The third glial class, oligodendrocytes, supports neurons by wrapping the neurons' long, wiry fibers called axons in myelin.

## Sharing the spotlight



Oligodendrocytes (green) and astrocytes (red) are glial cells that influence the way chemical and electrical signals travel from neuron to neuron (blue) and may shape the way information is stored. A third type of glia, microglia (yellow), help protect the brain.

# Glial functions

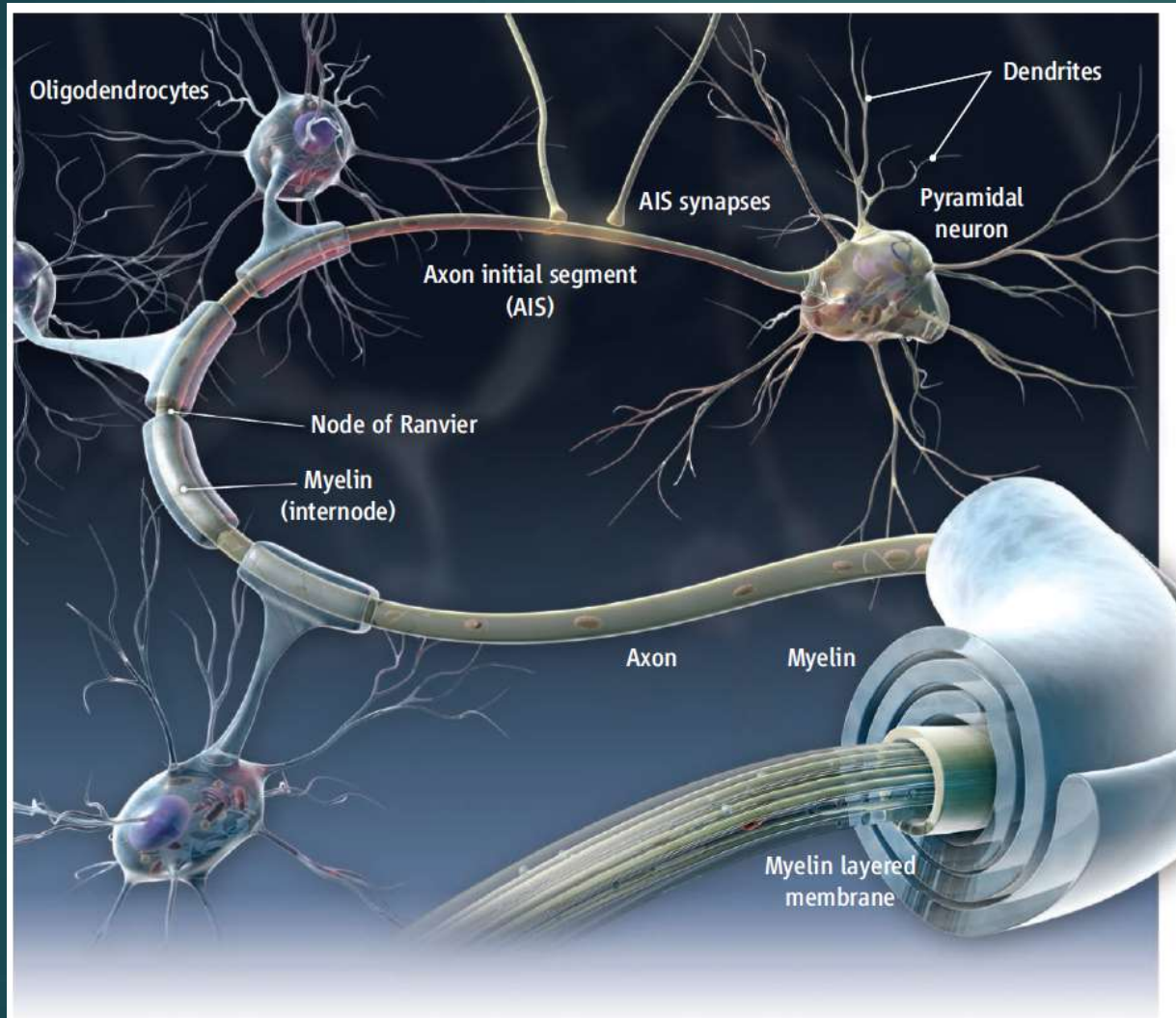
## ▶ Oligodendrocytes:

- ▶ Form myelin around neurons, substantially increase signal speed. It takes a signal 30 milliseconds to cross from the left to the right side of the brain on myelinated axons. A similar signal takes about 300 milliseconds on un-myelinated axons.
- ▶ Provide vital metabolic support for axons
- ▶ Problems with these cells are implicated in multiple sclerosis, amyotrophic lateral sclerosis and inhibition of repair after spinal cord injury

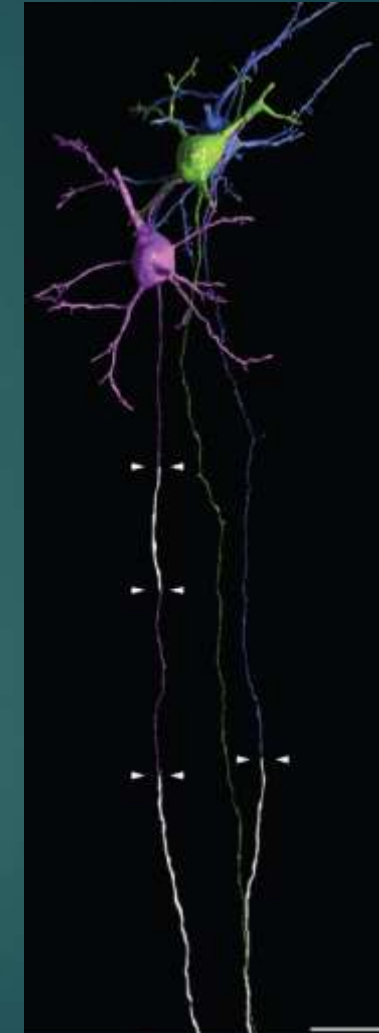
## ▶ Astrocytes:

- ▶ Wrap around synapses & BBB blood vessels, influencing signaling and nerve birth and growth; astrocytes talk among themselves using calcium signals, but also used the signals to communicate with neurons.
- ▶ Respond to injury by producing proteins
- ▶ When dysfunctional, implicated in many neurological and psychiatric disorders, such as epilepsy and schizophrenia

# Myelin: Oligodendrocytes



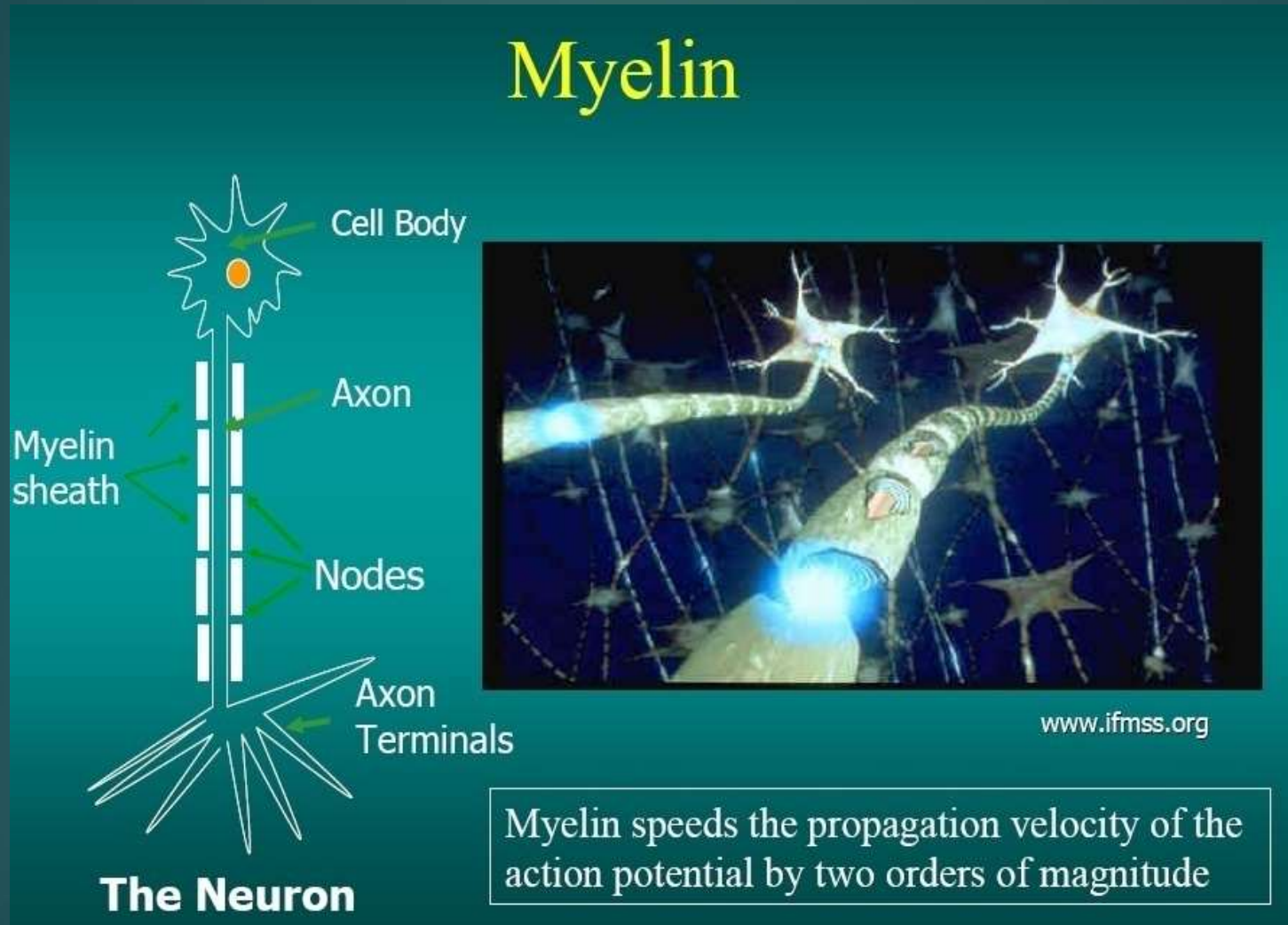
**Intermittent myelination.** Myelination of layer II/III pyramidal neurons of the cerebral cortex is illustrated, with a long axon initial segment and segments with variable lengths of unmyelinated axon.



**Not all Axons  
are mylenated**



# Myelin: 176,000 KM of Myelinated Axons

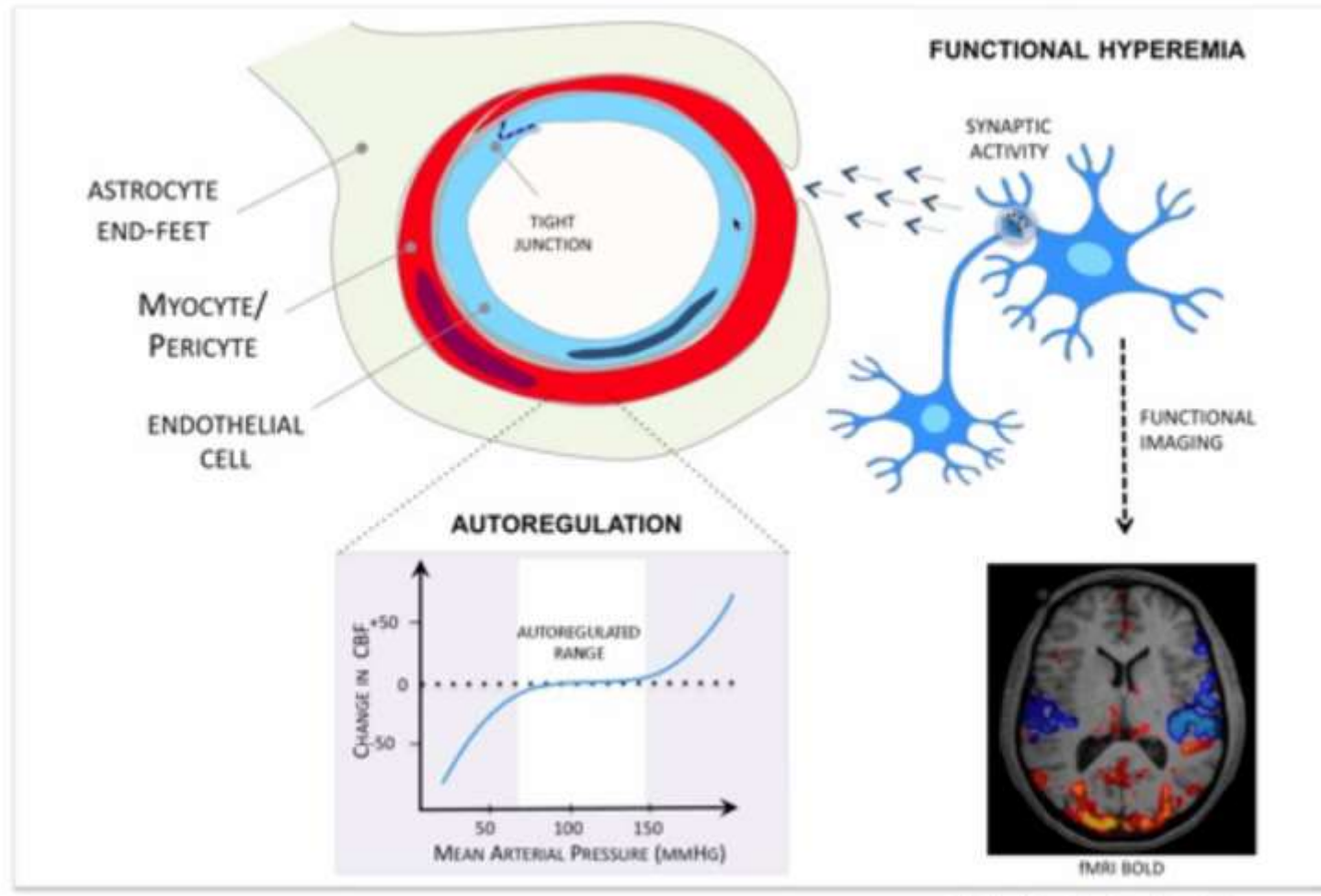


Myelinated speed: 100m/s; unmyelinated speed - less than 1m/s

# Blood Brain Barrier

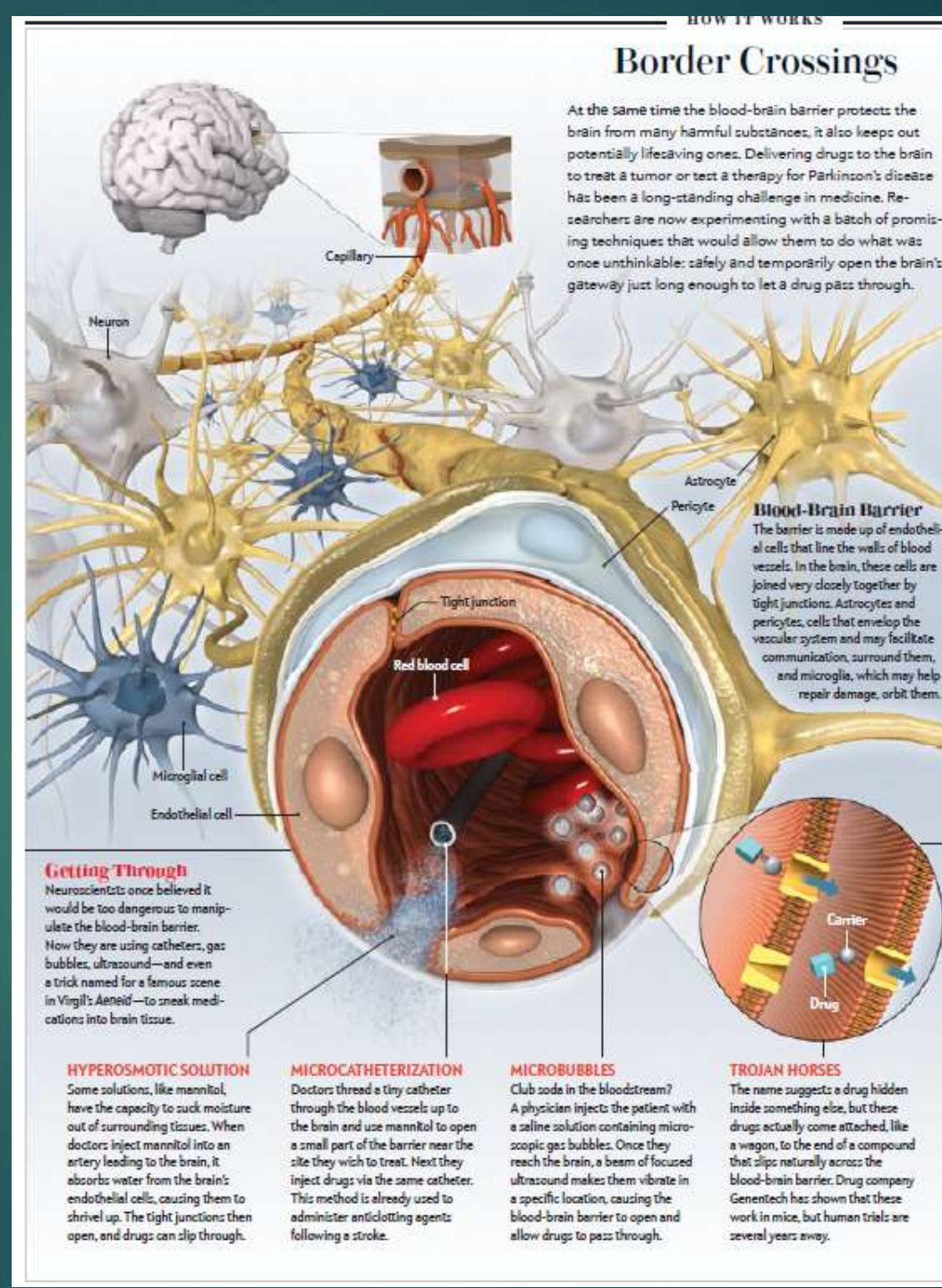
BBB: blood flow  
Produces BOLD  
Signal on fMRI,  
not neuron activity

## Mechanisms of Cerebrovascular Regulation



## Blood Brain Barrier – blood vessels surrounded by:

- Endothelial cells
- Pericytes
- End feet of Astrocytes

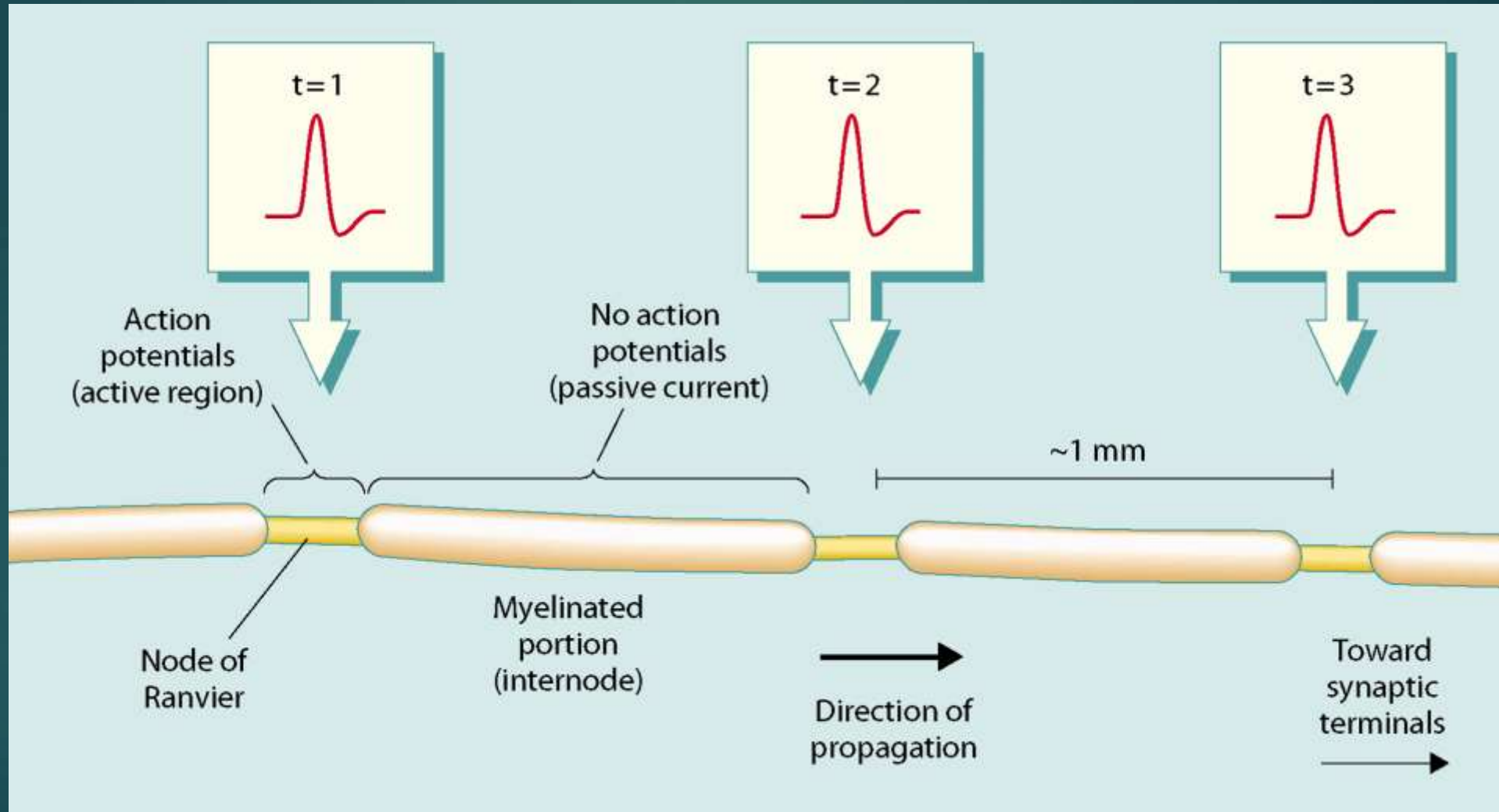




# Men have more

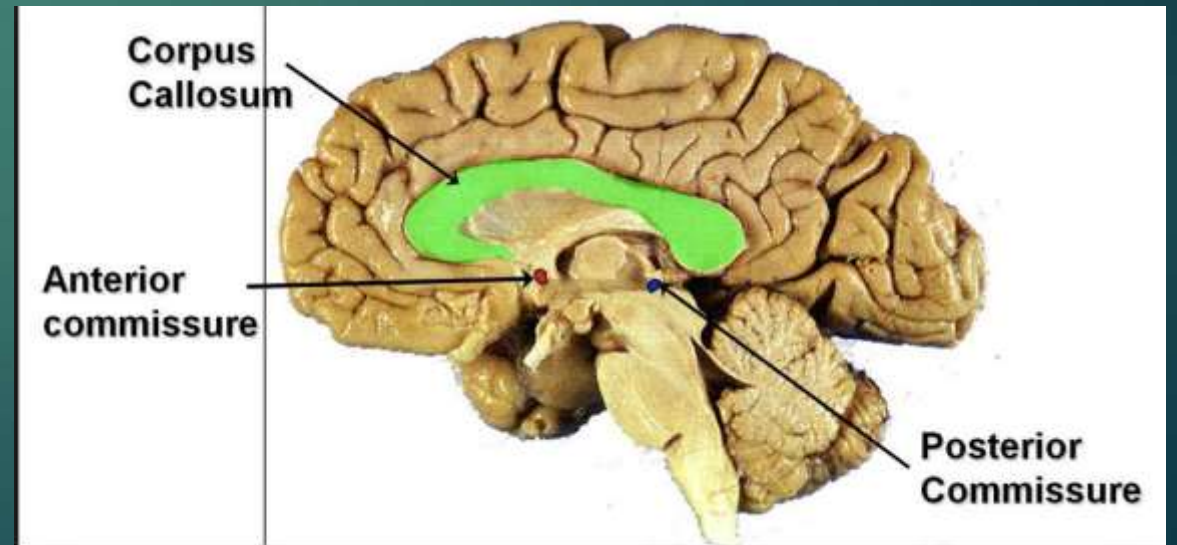
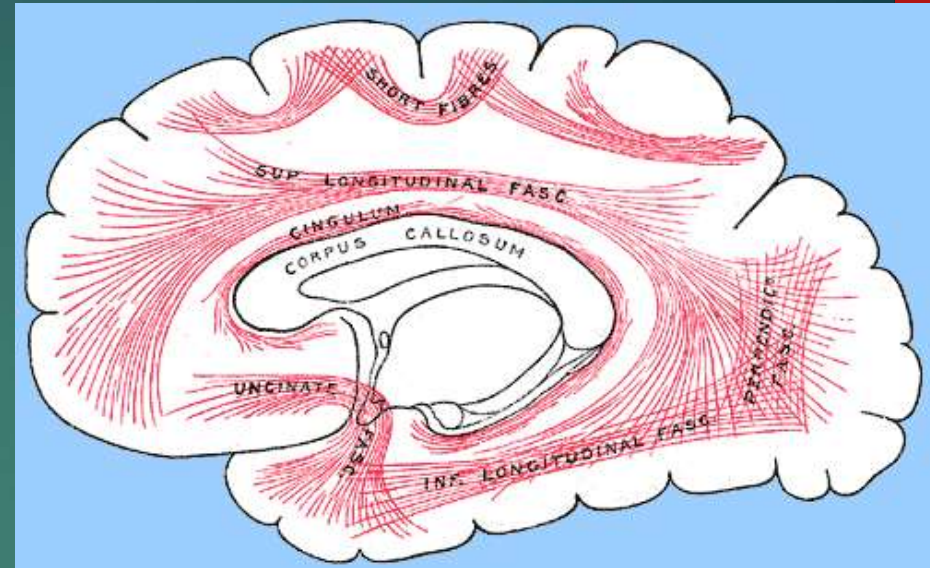
- ▶ Men have more white matter than females both in volume and in length of myelinated axons.
- ▶ At the age of 20, the total length of myelinated fibers in males is 176,000 km while that of a female is 149,000 km.
- ▶ There is a decline in total length with age of about 10% each decade such that a male at 80 years of age has 97,200 km and a female 82,000 km.
- ▶ Most of this reduction is due to the loss of thinner fibers.

# Electrical Conduction in Myelinated Axons

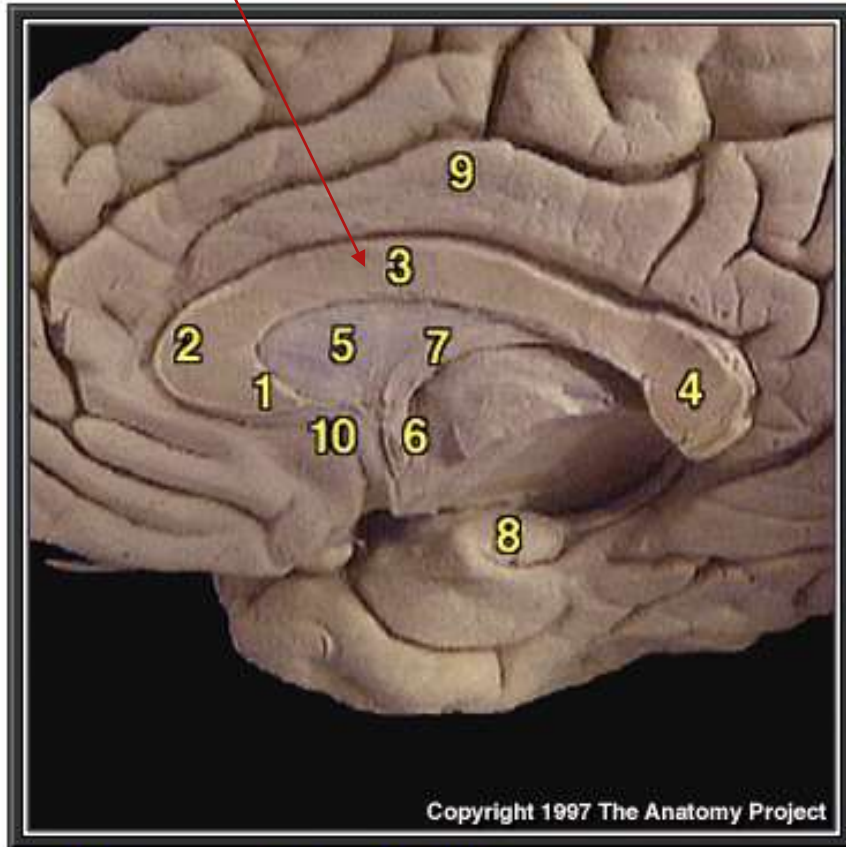


# White matter is

- ▶ Corpus callosum
- ▶ Fasciculi
  - ▶ superior longitudinal
  - ▶ arcuate
  - ▶ inferior longitudinal
  - ▶ uncinate
- ▶ Anterior commissure
- ▶ Posterior commissure



# Corpus callosum: 200 million axons



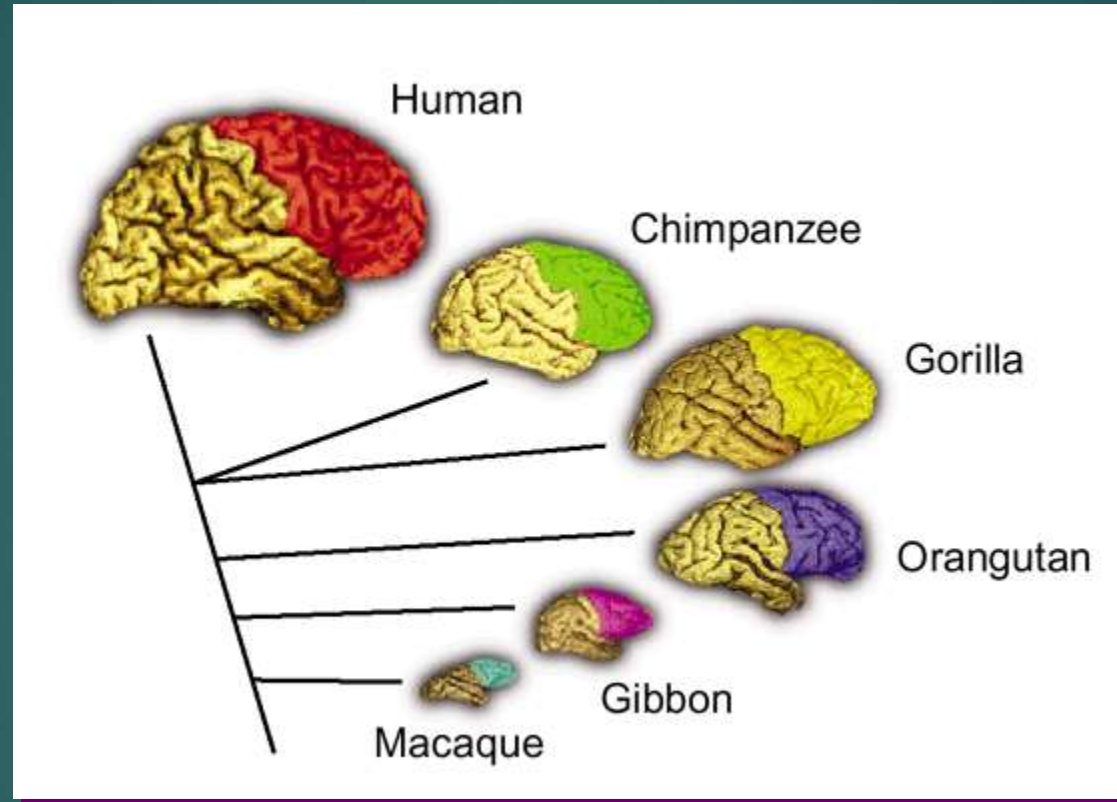
1. Rostrum of corpus callosum
2. Genu of corpus callosum
3. Body of corpus callosum
4. Splenium of corpus callosum
5. Septum pellucidum
6. Anterior commissure
7. Fornix
8. Hippocampus
9. Cingulate gyrus
10. Paraterminal gyrus

# Anatomy 2

- ▶ Commissural fibers (Corpus Callosum, Anterior Commissure, Hippocampal Commissure)
- ▶ Association Fibers (Short between gyri, Long fasciculi), Projection fibers (Internal Capsule)
- ▶ Asymmetry: Left Superior Temporal (planum temporale) enlarged because of greater myelination
- ▶ Speed of processing of information is specialization of white matter
- ▶ The white matter does not have as generous a blood supply as the gray matter and is more susceptible to ischemia.
- ▶ Leuko = white



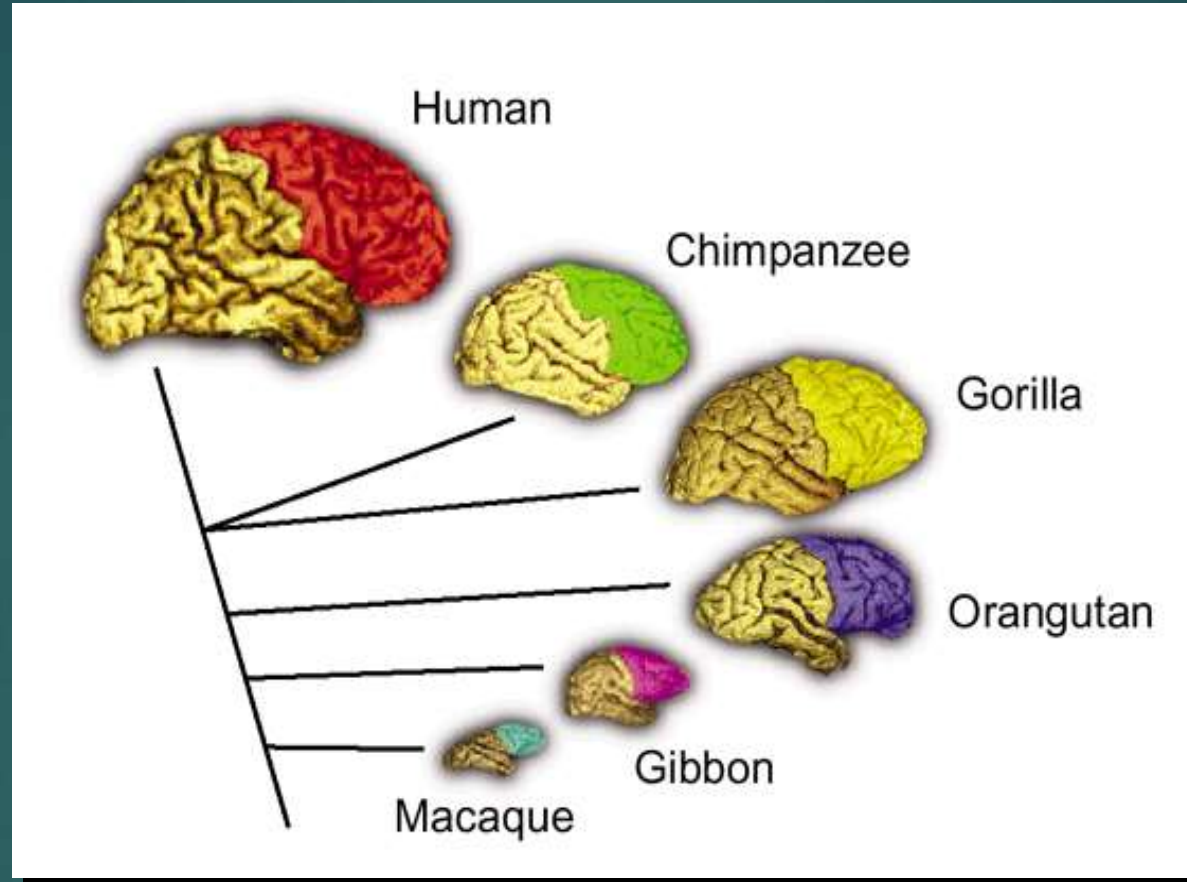
# Frontal Lobes not bigger in Humans: 35% in all Primates



The evolutionary relationships among the species are indicated by the connecting lines. Semendeferi and colleagues found that human frontal lobes are not disproportionately larger than predicted for a primate brain of its size.

(Figure courtesy of K. Semendeferi and H. Damasio)

# Evolution of Prefrontal Lobes: Humans do not have larger frontal lobes



35% in all primates; **humans greater white matter:**  
greater frontal gyral white matter; greater connectivity

# Evolution: Humans have more WM

- ▶ Richer interconnectivity:
  - ▶ Relative volume of white matter is larger in humans
  - ▶ Humans exhibit unique patterns of WM distribution
  - ▶ Neural connectivity has increased in humans

# Distributed & Parallel Processing Networks:

## Connectivity networks

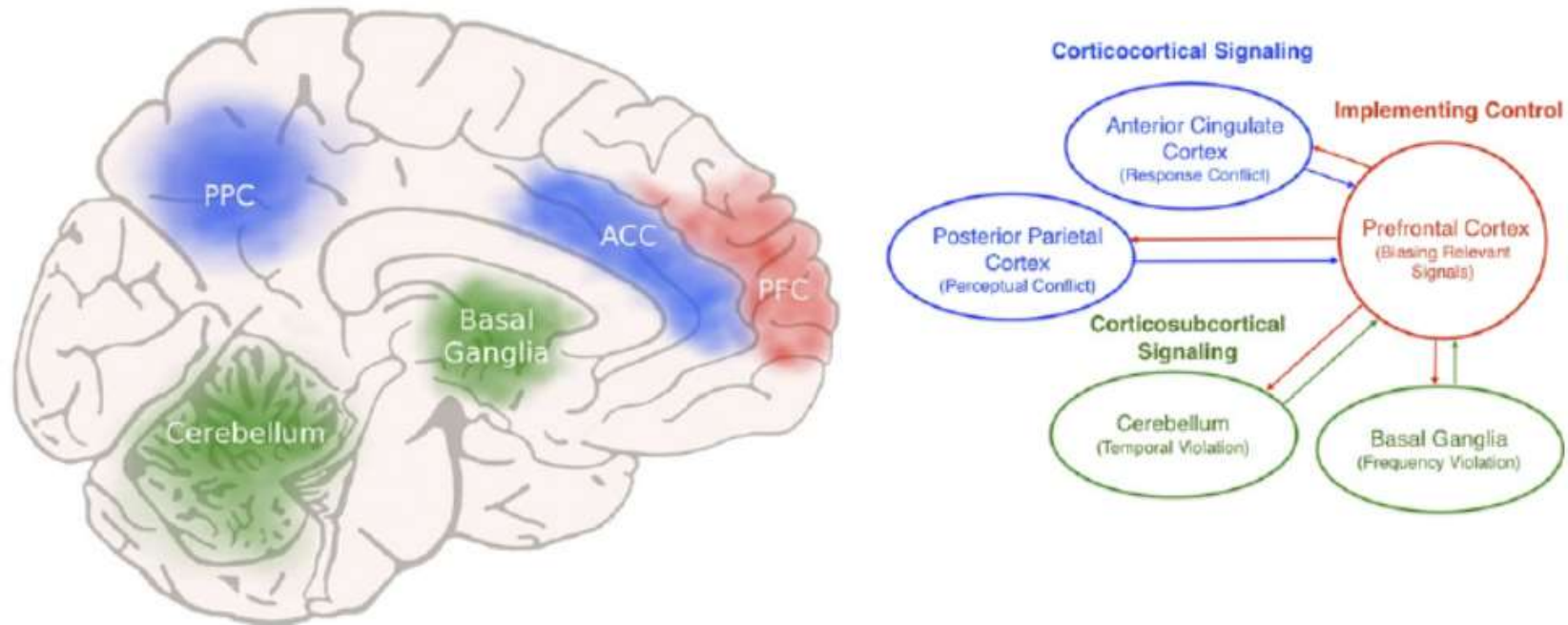
- ▶ Ways brain is neuroanatomical organized into networks:
  - ▶ Extensive neuron to neuron connections
  - ▶ Neurotransmitter systems
  - ▶ Functional areas organized via heteromodal connections
  - ▶ White matter fiber tracts – short to distant
  - ▶ Multiple processing networks: i.e. semantic memory, language, attention, etc.
  - ▶ Hub regions, i.e. expressive, receptive
  - ▶ Connectivity networks

# Dynamic networks model

- ▶ Brain isn't just functionally modular. While certain regions are specialized to process certain types of information and are active during certain tasks, they are all part of distributed functional networks.
- ▶ The CNS is an integrated, wide, dynamic network made up of cortical functional epicenters connected by both short-local and large-scale white matter fibers.
- ▶ Brain function results from parallel streams of information dynamically modulated within an interactive, multimodal, and widely distributed circuit.

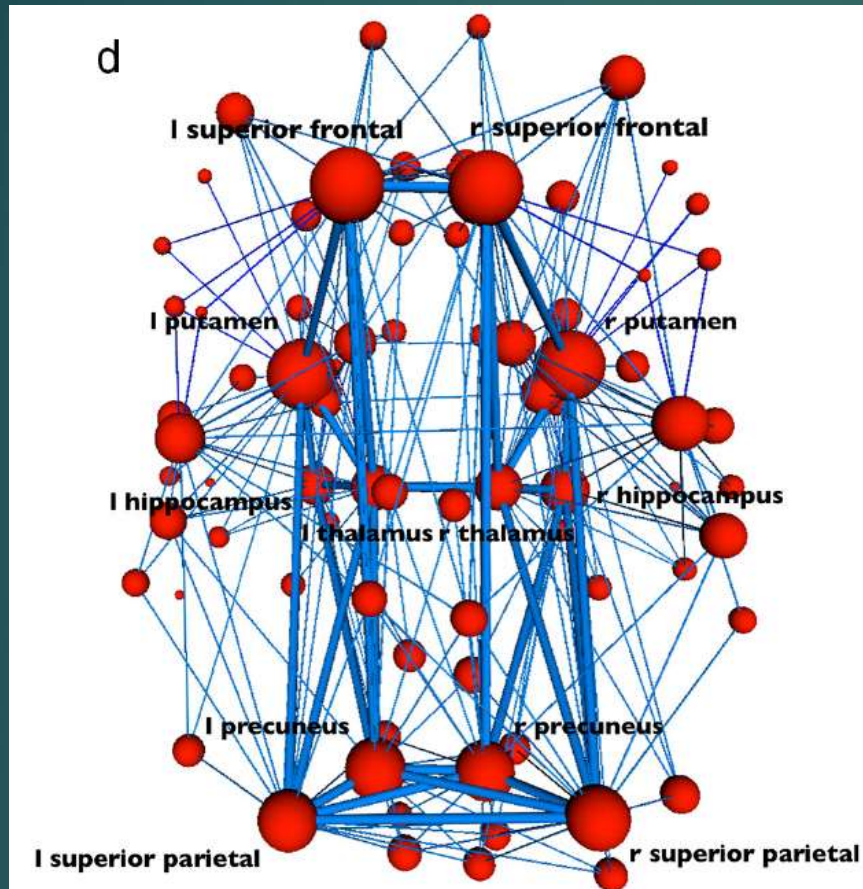
# Network example: ADHD

Figure 2. Brain networks implicated in attention-deficit/hyperactivity disorder (ADHD). A network of structures, each with projections to and from prefrontal cortical areas mediates the cognitive control of attention and behavior, and dysfunction in this network has been implicated in ADHD, particularly in the core symptoms of the inattention subtype. Anterior cingulate (ACC) and posterior parietal cortex (PPC) detect conflicts in information processing, recruiting prefrontal cortex (PFC) to provide top-down bias signals, resolving conflicts and enhancing control. Cortico-subcortical signals originating in the basal ganglia and cerebellum convey critical information about violations in the expected frequency and timing of events, respectively.

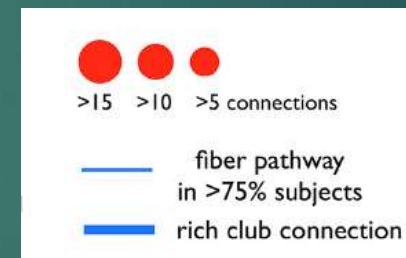




# 12 Rich World Hubs: central areas and freeways



Bilateral frontoparietal regions, including precuneus, superior frontal and parietal cortex, hippocampus, thalamus, and putamen are individually central & also densely interconnected, together forming a rich club.



Connections between rich-club regions (dark blue) and connections from rich-club nodes to the other regions of the brain network (light blue). The figure shows that almost all regions of the brain have at least one link directly to the rich club. Brain lesions that damage one of the rich club hubs will have more serious behavioral effects (3x more) than damage to non-hub area.

# White Matter and Default Network

- ▶ Functional connectivity between the posterior cingulate and hippocampus and the functional connectivity across the entire
- ▶ DMN is based on distinct pattern of anatomical connectivity within the cerebral white matter.
- ▶ People with Alzheimer's disease tend to have less activity in the default mode network and they tend to have less connectivity



# Juggling and WM increase

- ▶ A 2009 paper by Jan Scholz and colleagues used diffusion tensor imaging (DTI) to demonstrate changes in white matter volume (increased white matter volume in the training group, specifically the area underlying the right posterior parietal sulcus) as a result of learning a new motor task (e.g. juggling).
- ▶ The study is important as the first paper to correlate motor learning with white matter changes.
- ▶ There was also grey matter density increase
- ▶ Piano players whose pyramidal tract integrity correlated with number of hours practiced (Bengtsson et al., 2005), and in neurologic patients, such as those with Broca's aphasia in whom the right arcuate fasciculus volume increased as Melodic Intonation Therapy improved language performance



## Brain Maturation ages 5-20

- ▶ Pruning away of synapses to neurons that are not used
- ▶ Increase in amount of white matter relative to grey neurons
- ▶ Increase in myelination of axons, which then can transfer information 1000s of times faster
- ▶ This improved connectivity of fewer more specialized neurons and networks creates behavioral maturity
- ▶ Crucial decision making frontal lobes are the last to mature
- ▶ Females are 2 years ahead in this maturation process.
- ▶ High variability: can fully mature at 13 or 30

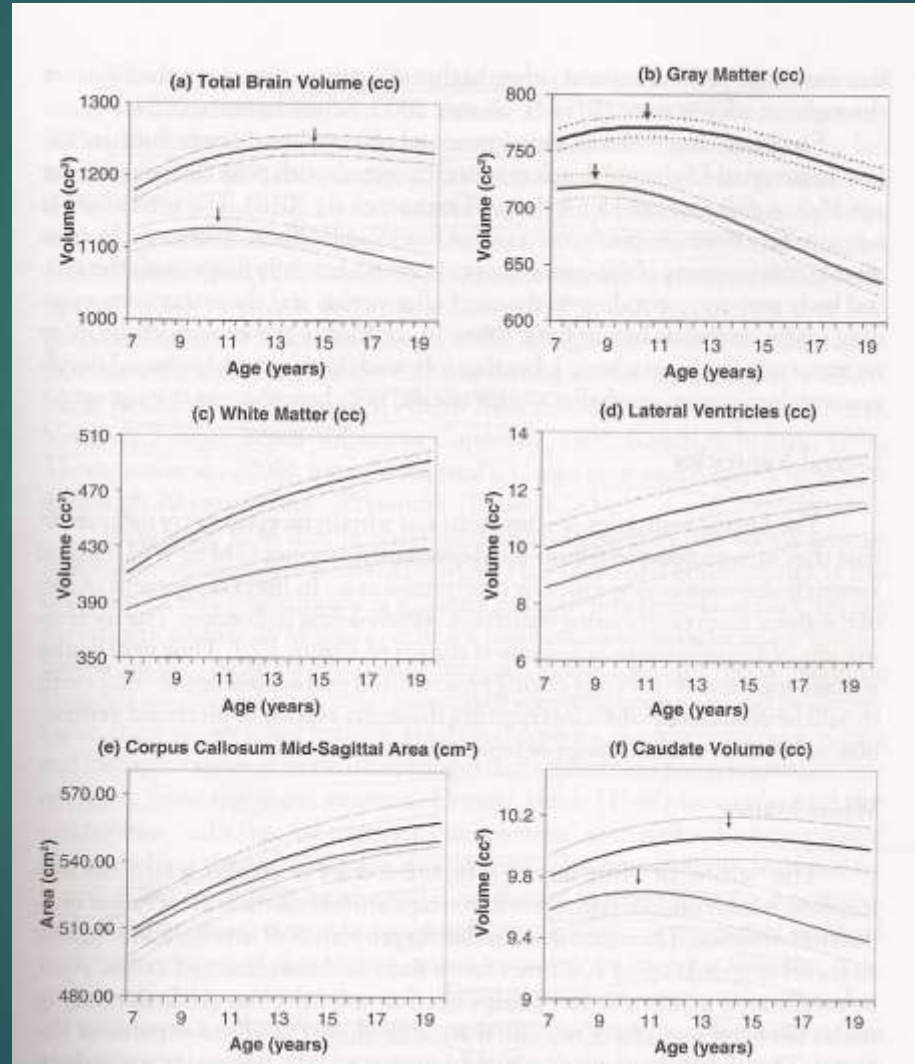
# During brain development, GM ↓↓, WM ↑↑

Brain Volume

White Matter & CC  
increase:

Increased processing  
speed (3000-fold  
increase in info  
transmission per sec)

Correlation with  
improved language,  
reading, inhibition,  
& memory functions




GM decrease

Ventricle  
increase

Boys vs. Girls

# Myelin Sheets on Axons Mature Slowly in Frontal Lobes.

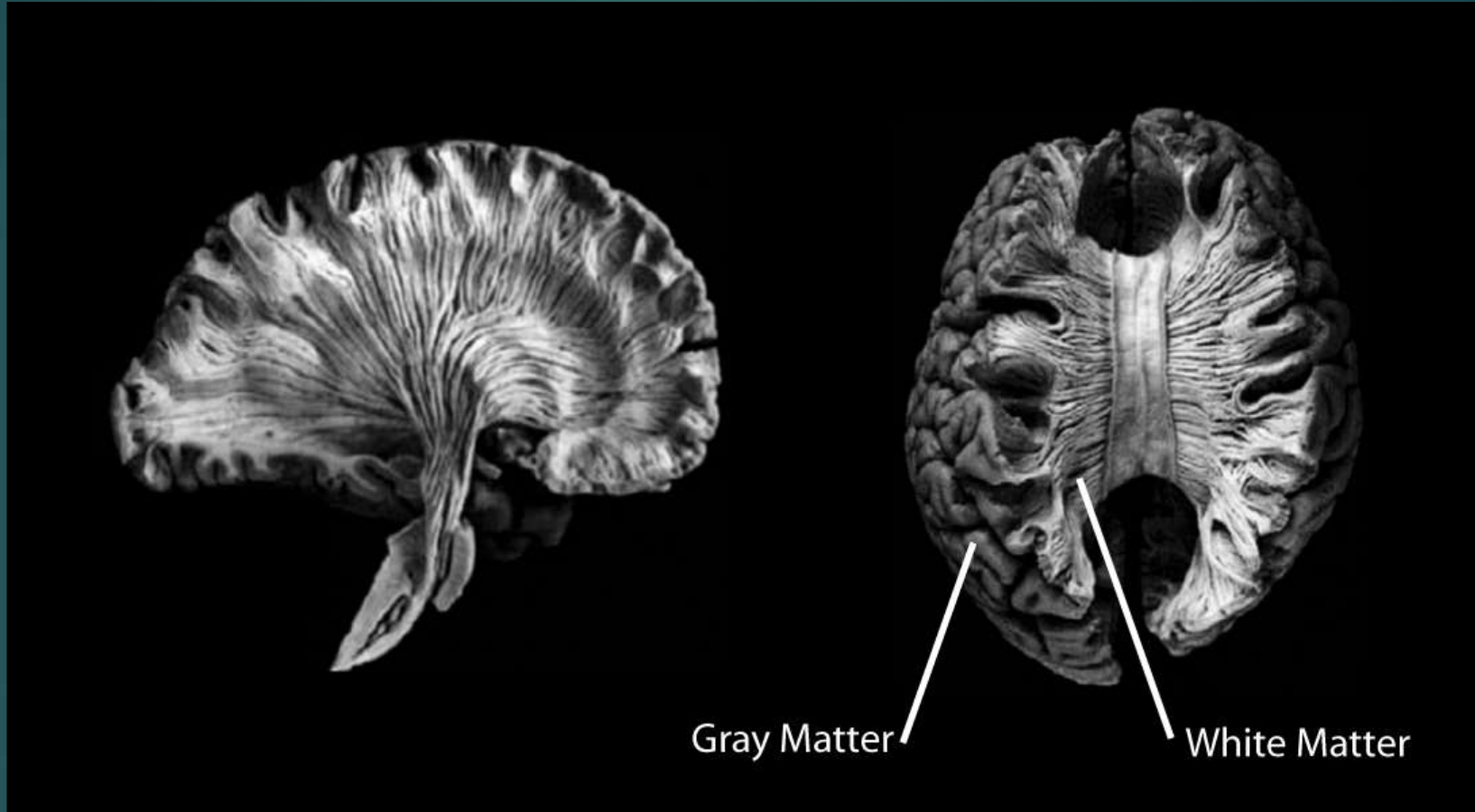## Regional Maturation: Myelogenetic Cycles



Taken from Yakovlev & Lecours, The Myelogenetic Cycles

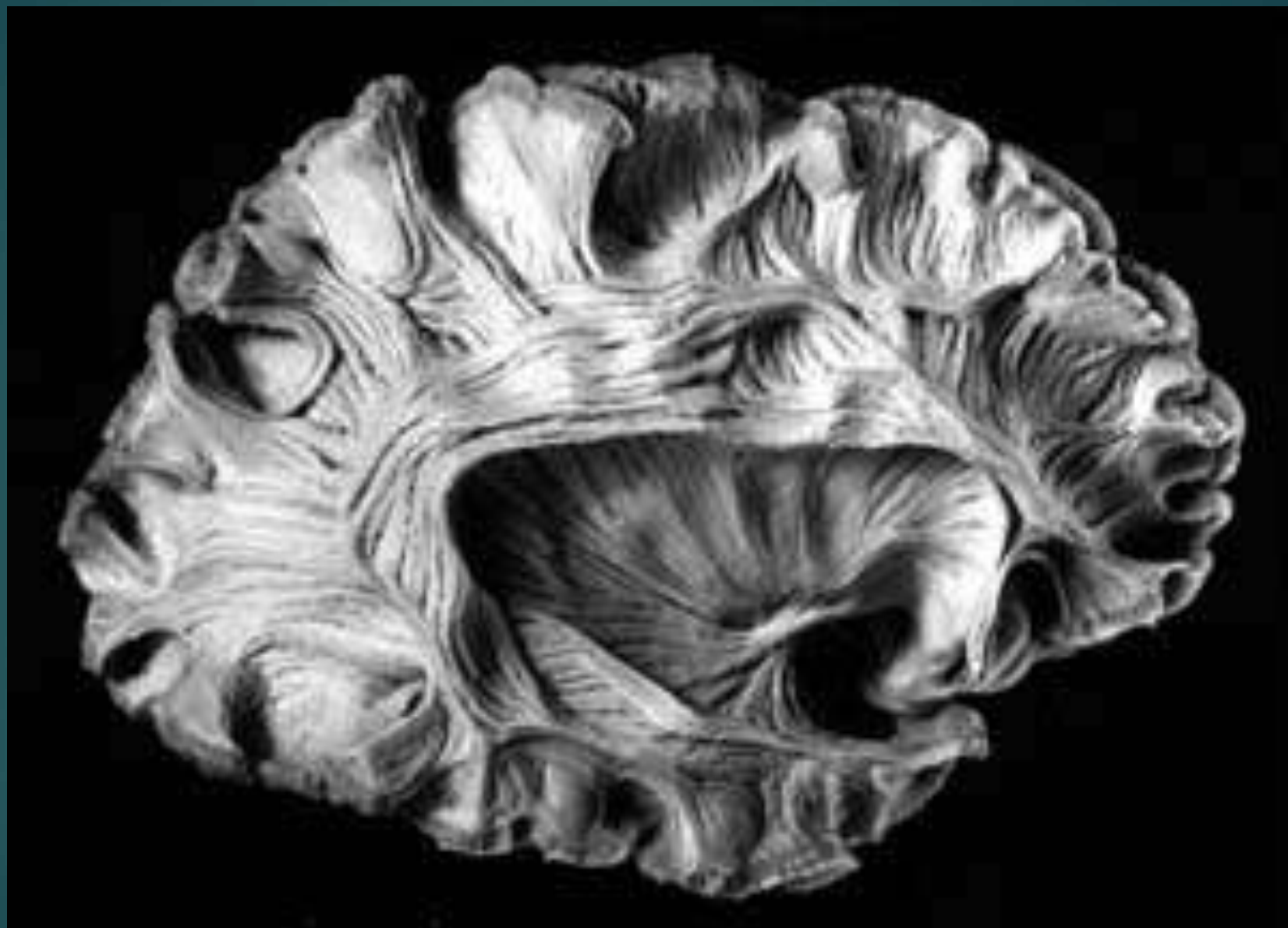White matter creates "greater bandwidth" and processing speed.

# The Human Brain: White Matter

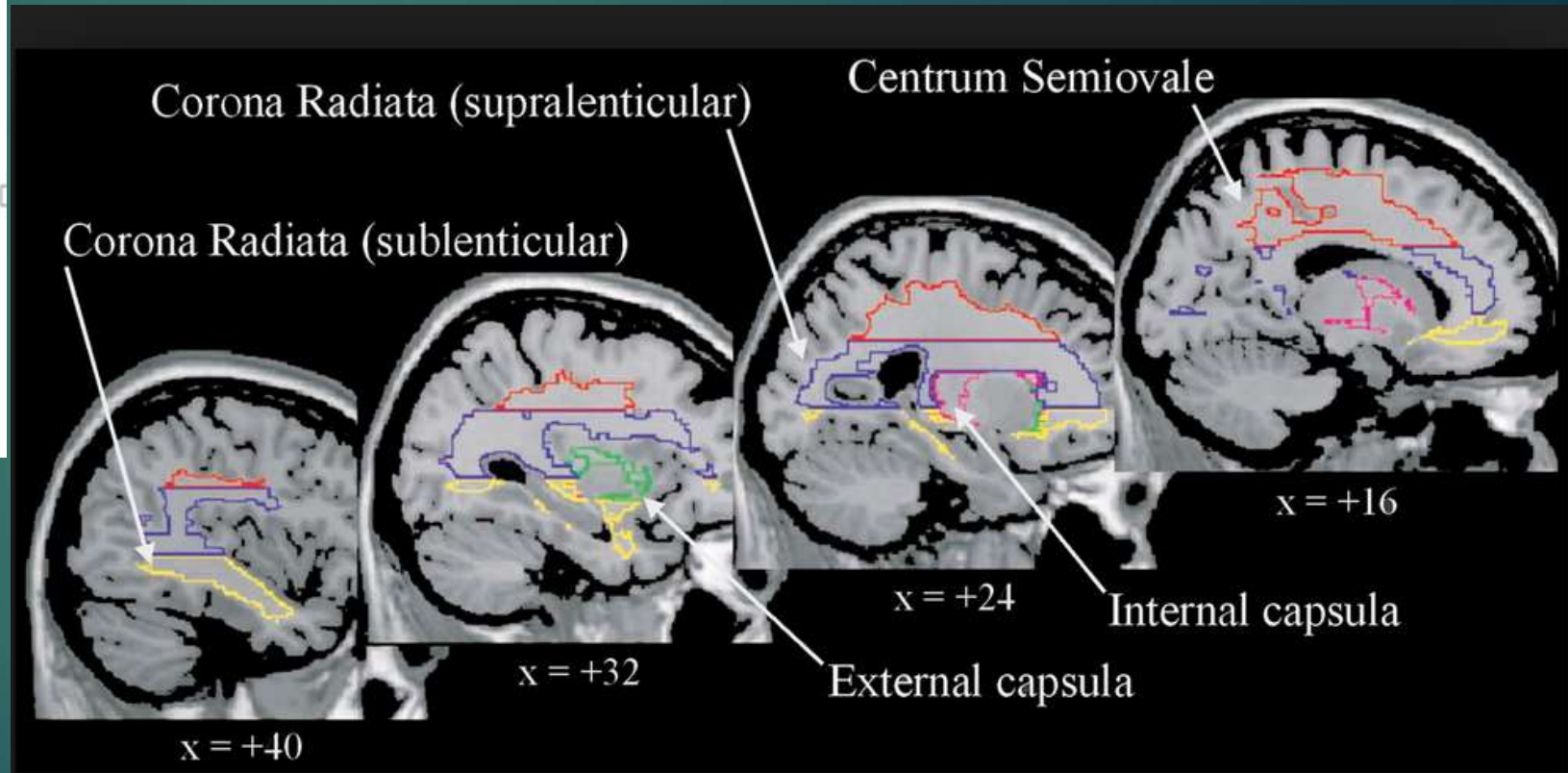
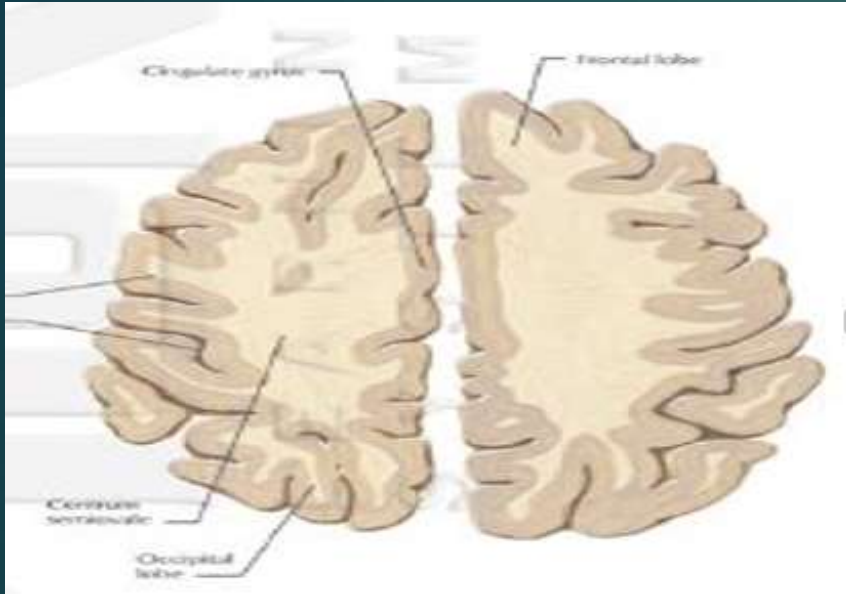


Williams et al., Iowa Virtual Hospital



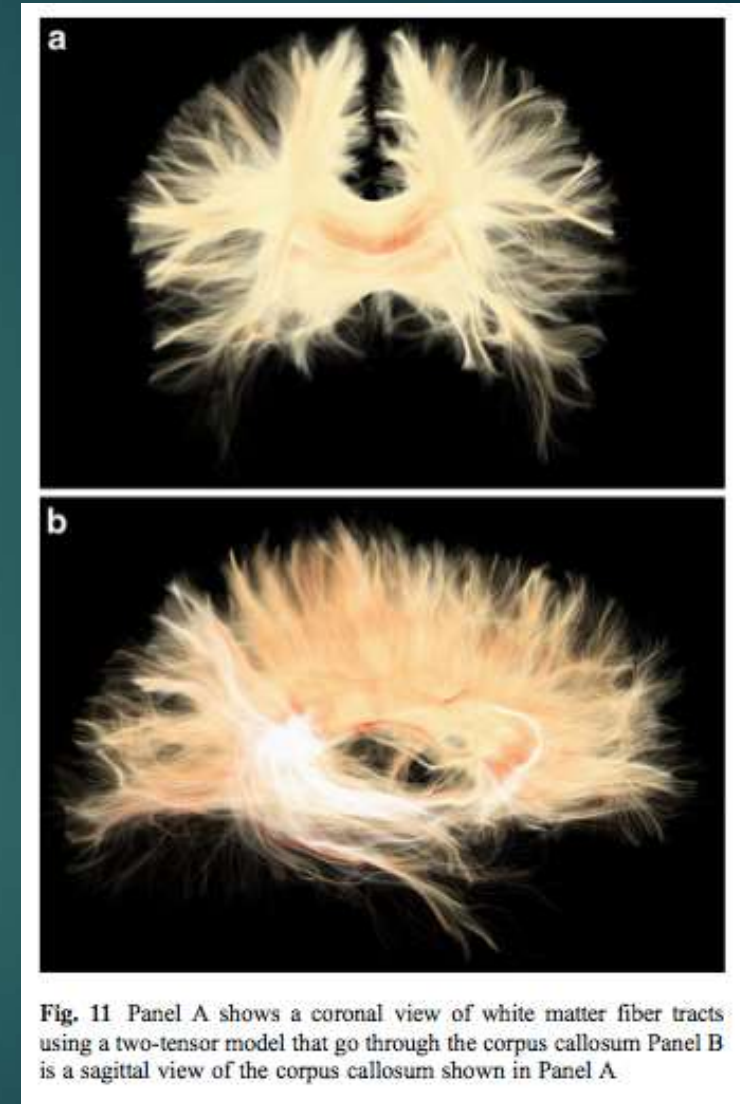


# Centrum Semiovale



# Diffuse Tensor Imaging

- ▶ Type of MRI sequence that uses the diffusion properties of water to detect microstructural tissue architecture.
- ▶ Best imaging technique available for detecting white matter integrity/damage, able to detect microscopic white matter damage and trace specific tracts of the brain

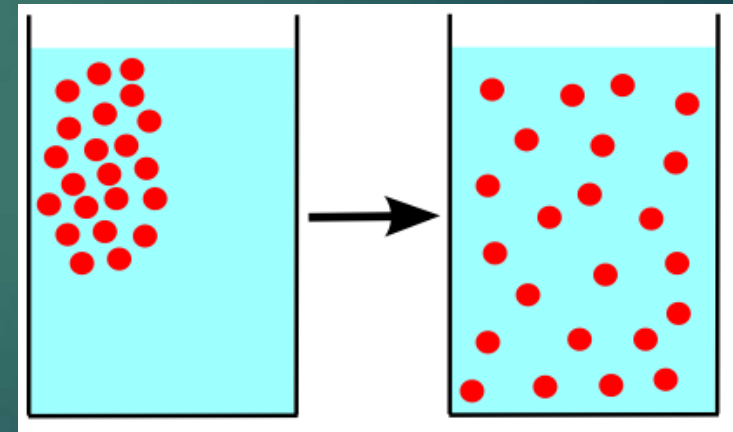




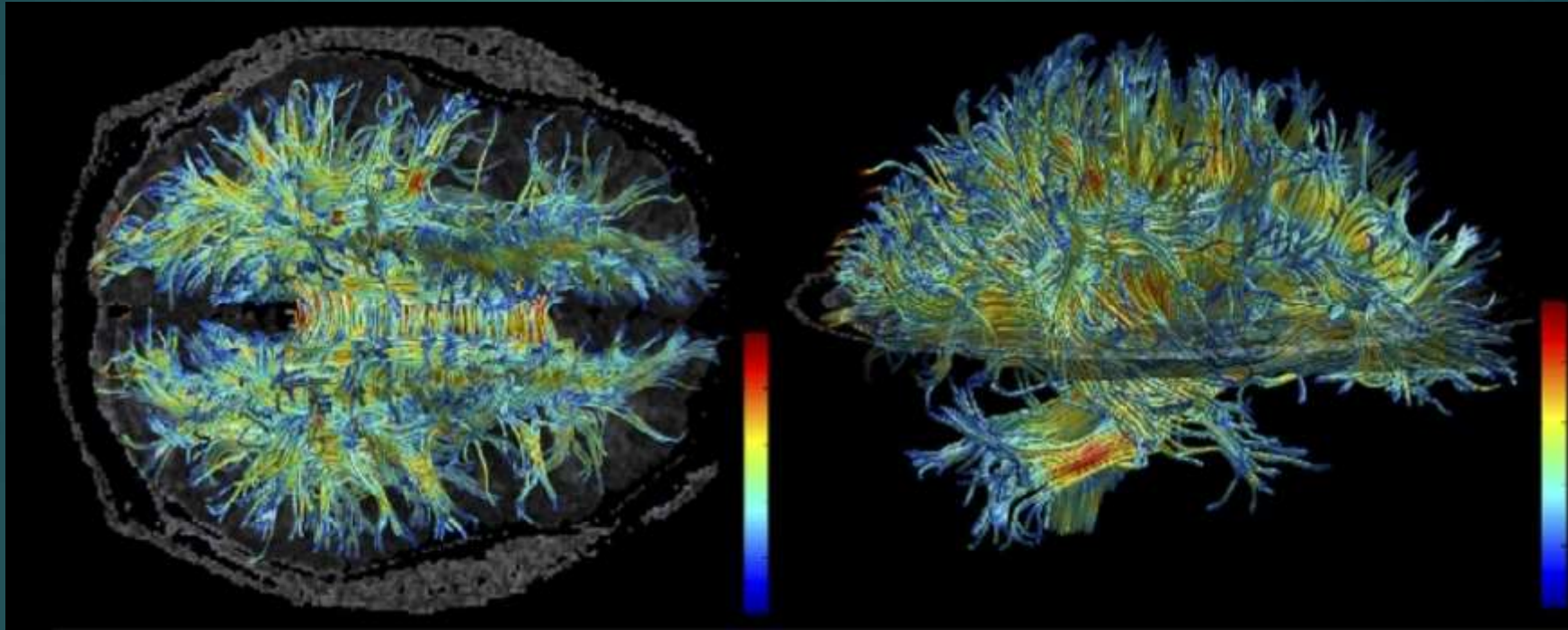
# Diffusion Tensor Imaging (DTI)

- ▶ Water Diffusion is restricted by axons, cell bodies, and myelin
- ▶ White matter diffusion
  - ▶ less diffusion = greater white matter integrity
  - ▶ fractional anisotropy (FA)
    - ▶ directionality of water molecule movement
    - ▶ **higher FA = greater white matter integrity** (anisotropy is good)
  - ▶ apparent diffusion coefficient (diffusivity)
    - ▶ diffusion of water
    - ▶ **lower values = greater white matter integrity**

**anisotropy**: property of being directionally dependent  
**isotropy**: identical properties in all directions




# Diffuse Tensor Imaging

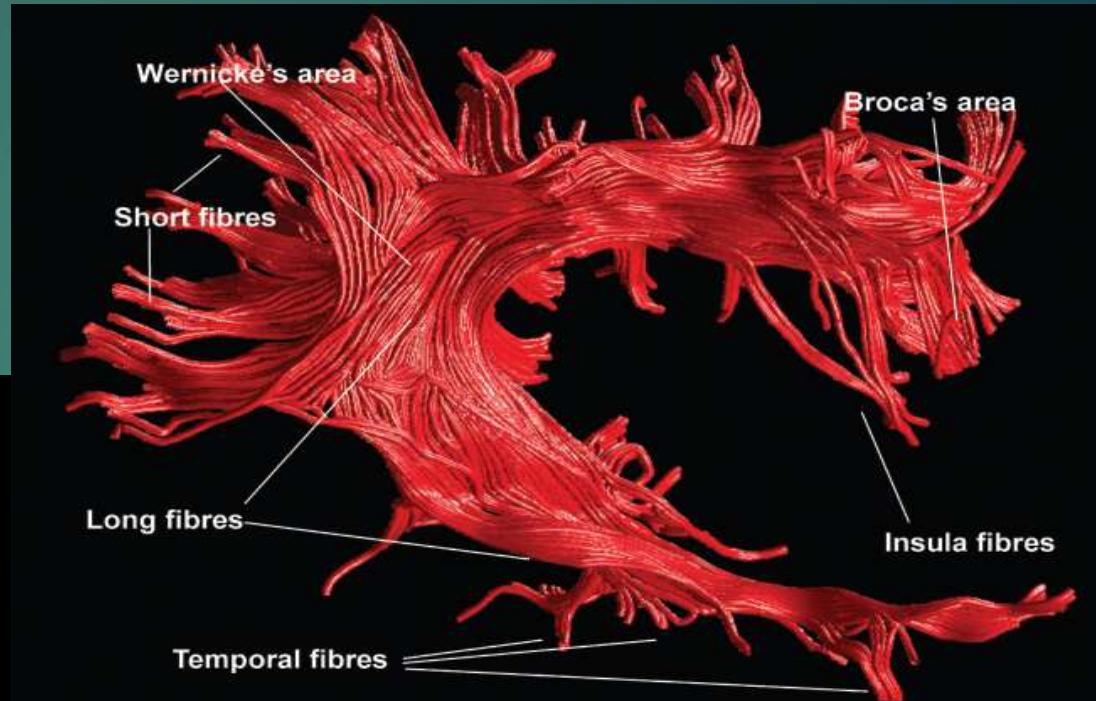
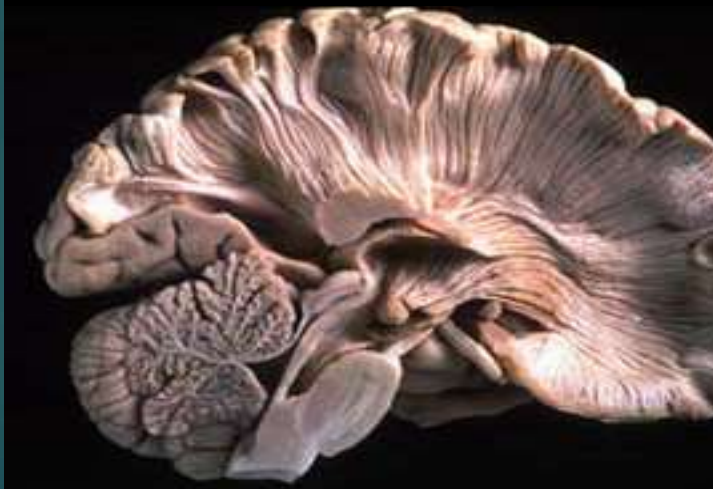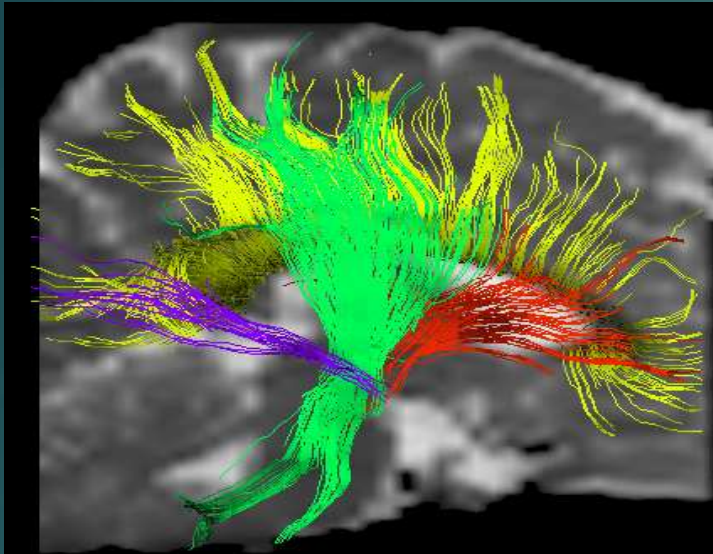


White matter in the human brain: axons between neurons

# Path Tracing: Complexity



# DTI – Tractography

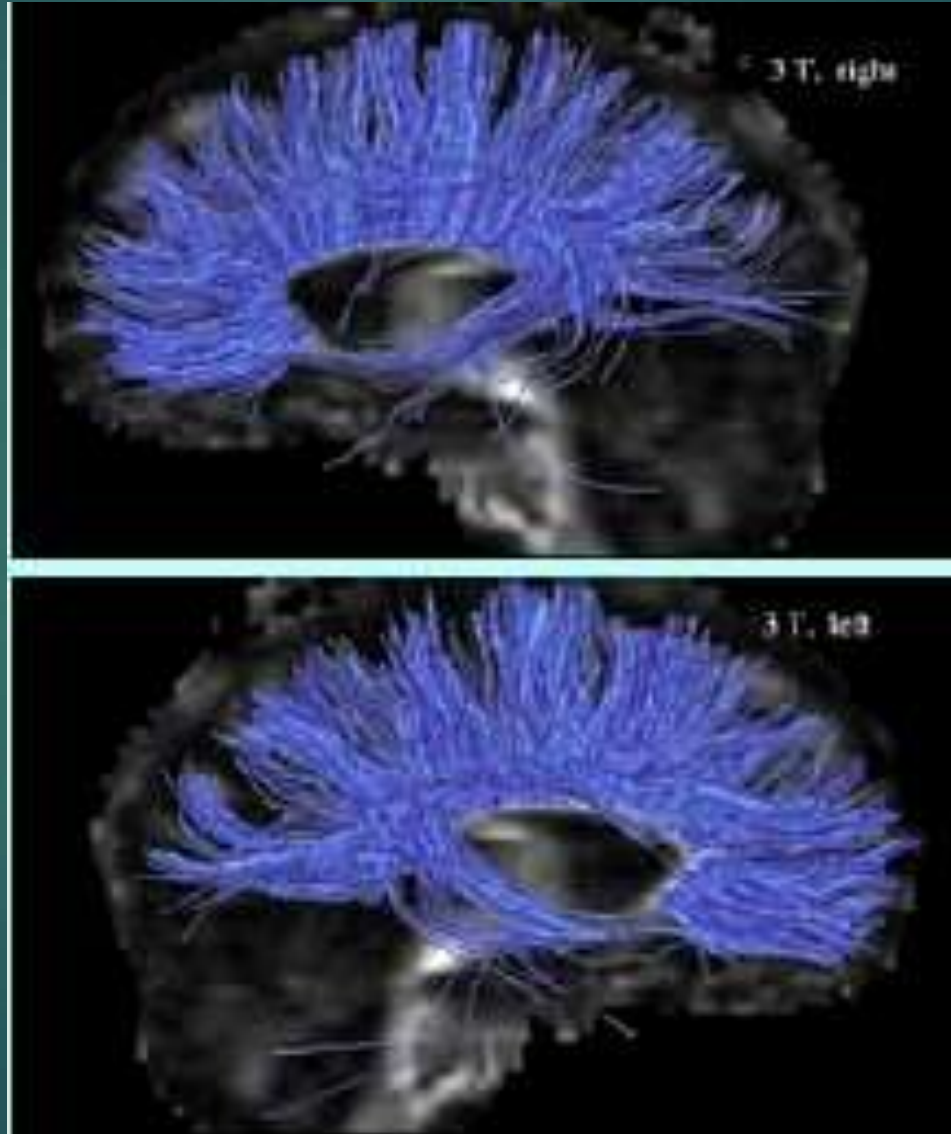


D. Jones – U Nottingham, UK

S. Mori - JHU

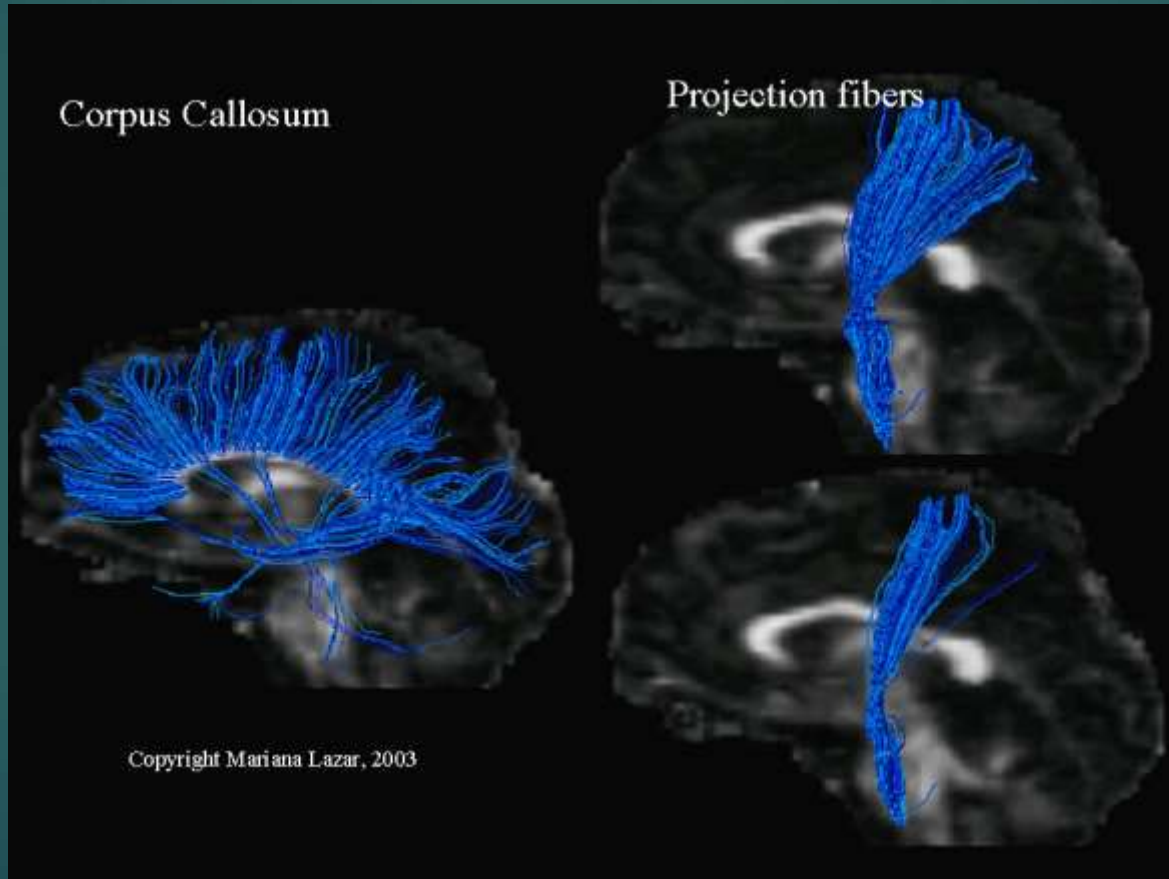


# White Matter: Diffusion Tensor MRI

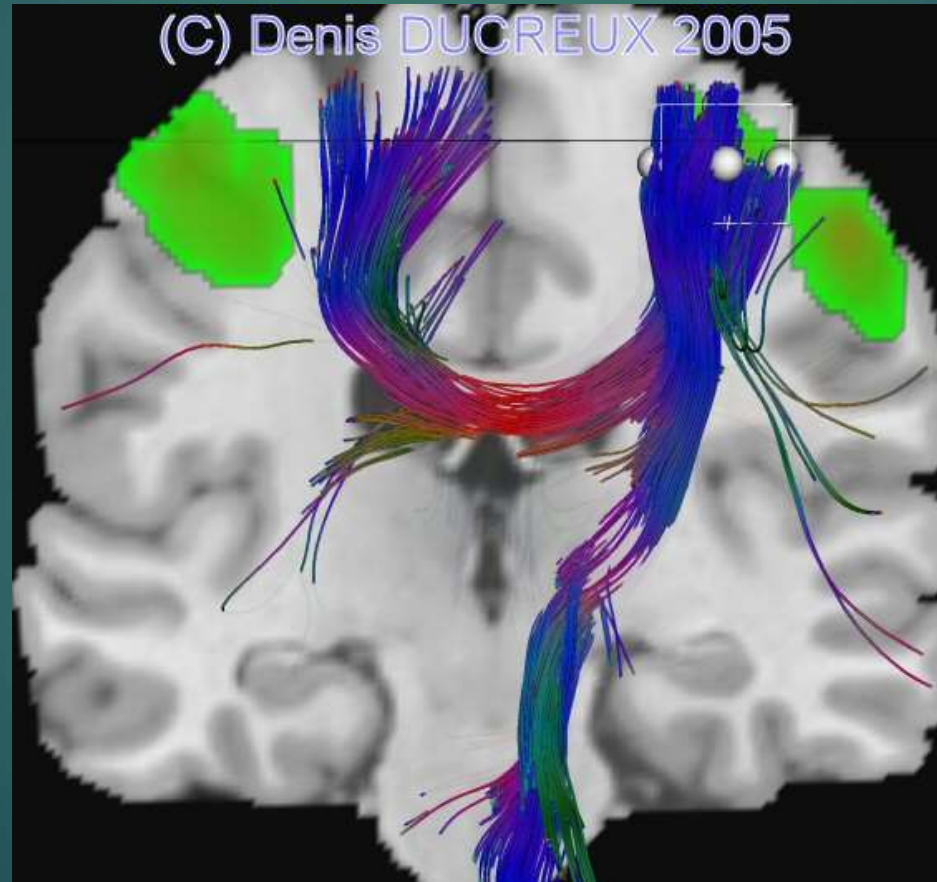





# Diffusion Tensor MRI



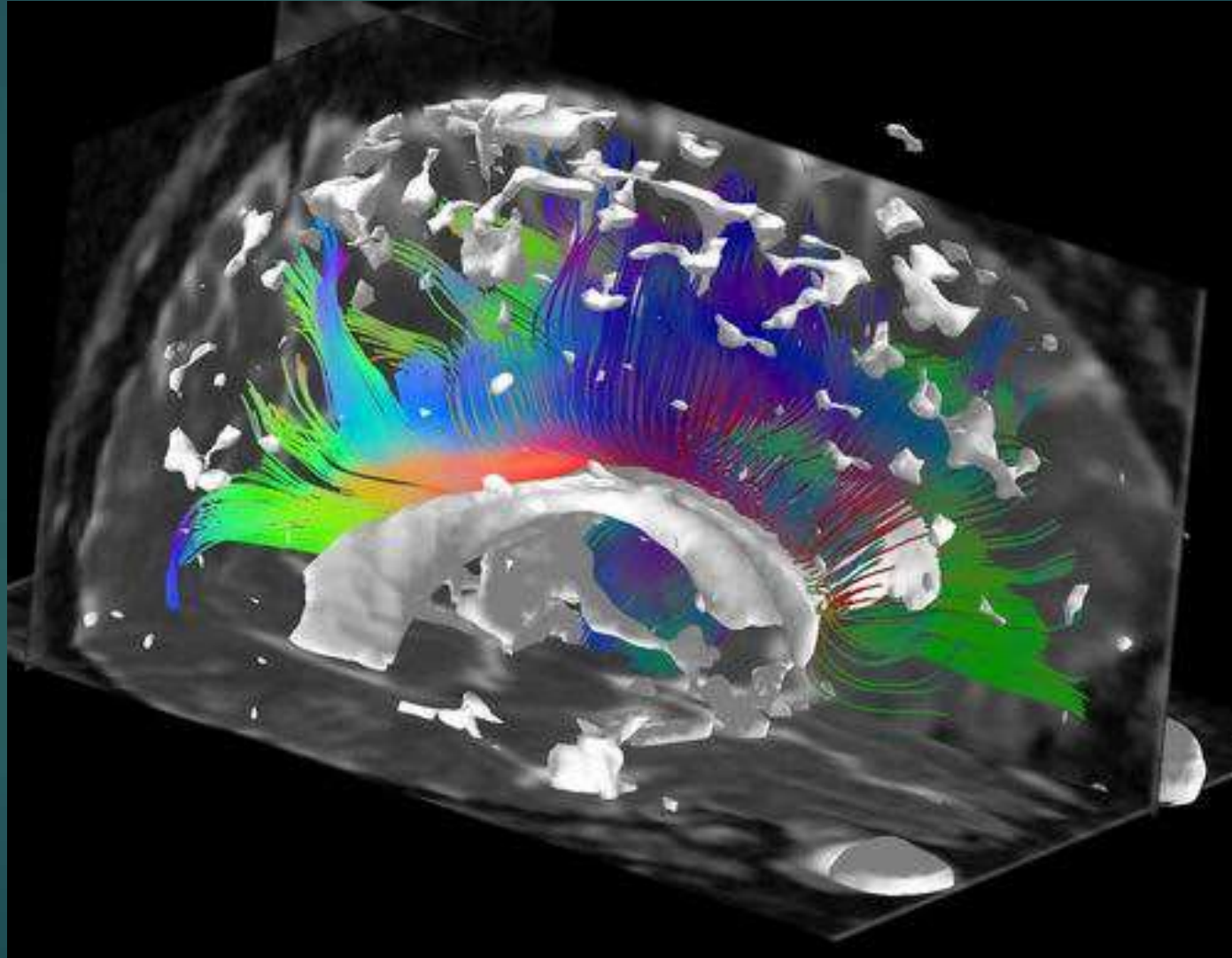
# White Matter: Diffusion Tensor MRI



# White Matter: Diffusion Tensor MRI

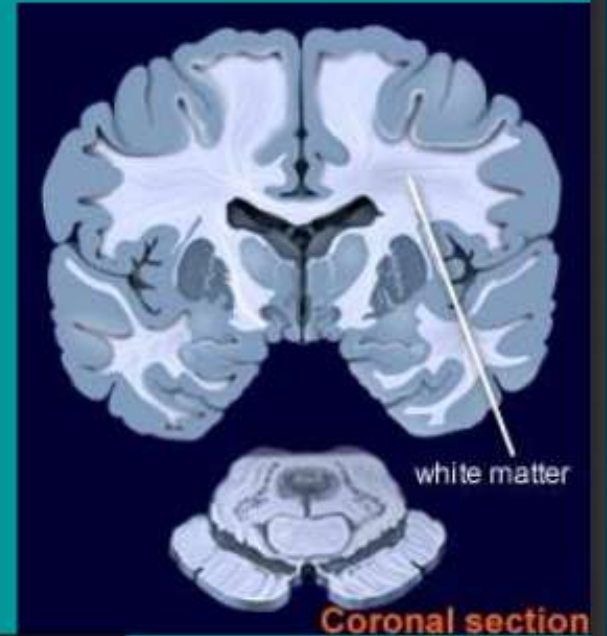


# White Matter: Diffusion Tensor MRI

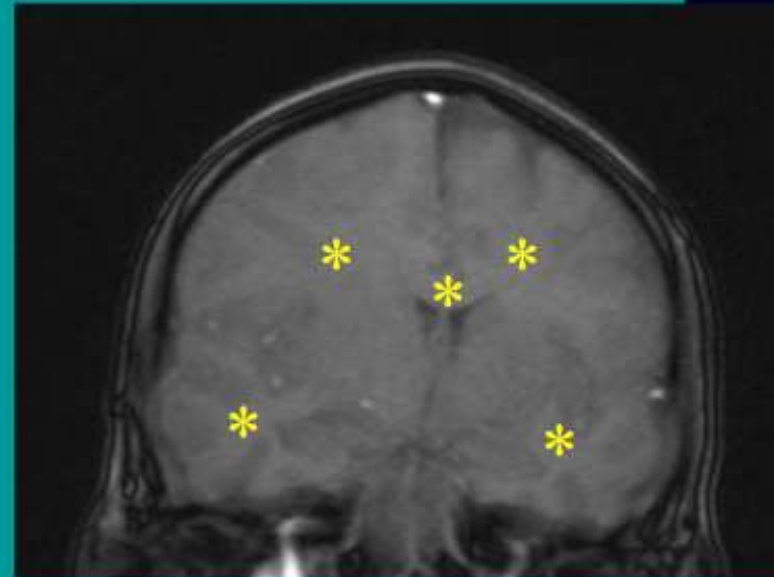




- In the brain, **WM** is located **centrally**
- WM contains **myelinated axons**
  - Composed of hydrophobic lipids
  - **High in fat & low in fluid** relative to gray matter (GM)
- **WM on CT** (looks white)
  - hypodense to GM
- **WM on MRI** (looks dark)
  - **Hyperintense to GM on T1**
  - Hypointense to GM on T2



[www.brainexplorer.org/glossary/white\\_matter.shtml](http://www.brainexplorer.org/glossary/white_matter.shtml)



Coronal T1 MRI

BIDMC PACS



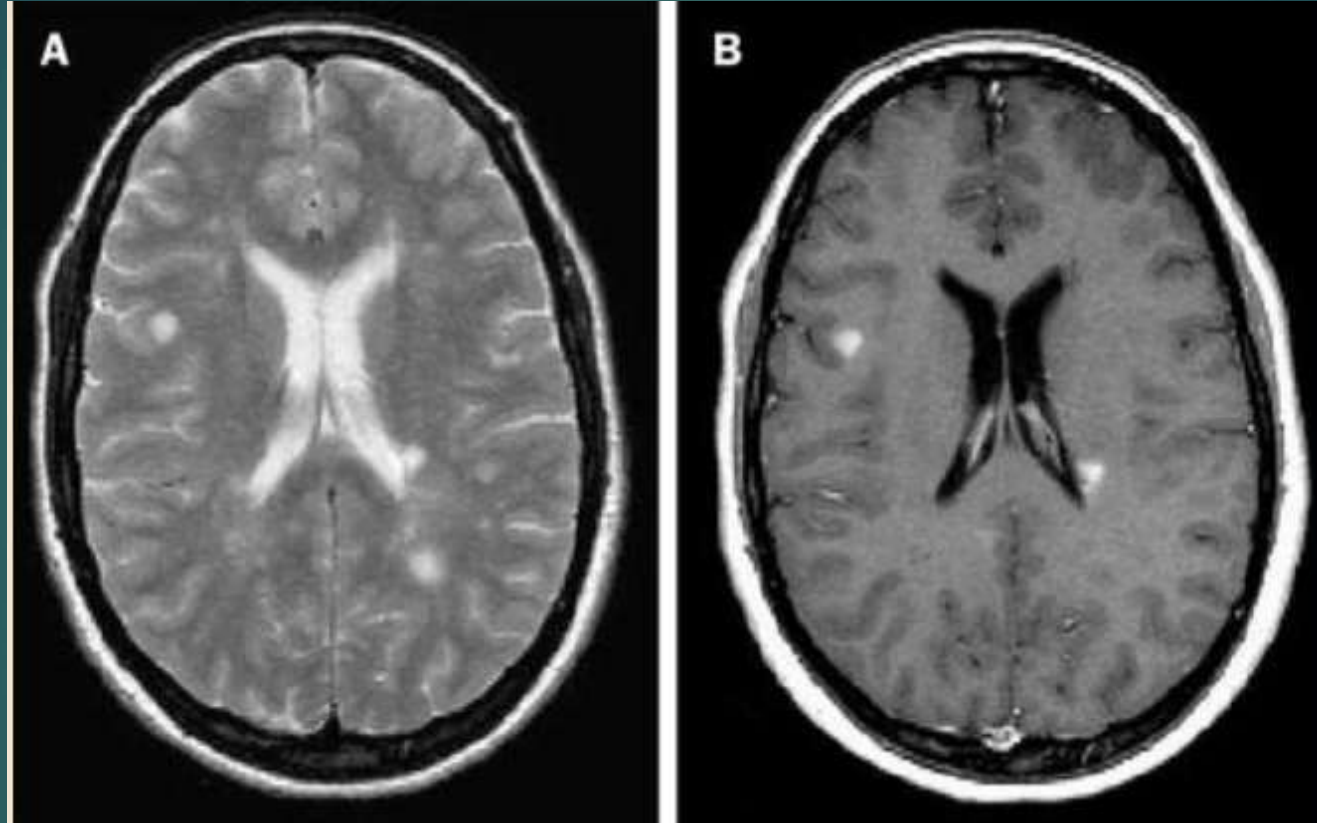
# T1 and T2 images

- ▶ MRI more sensitive for evaluation of WM disease than CT scan.
- ▶ Myelin has relatively short T2 and T1 relaxation times, primarily owing to its lipid content.
- ▶ Normal myelin is hypointense to gray matter (looks white) on T2-weighted images and hyperintense on T1-weighted images (looks black).
- ▶ If a disease process reduces the myelin content, the white matter becomes less hydrophobic and takes on more water.

## T2 better for WM visualization

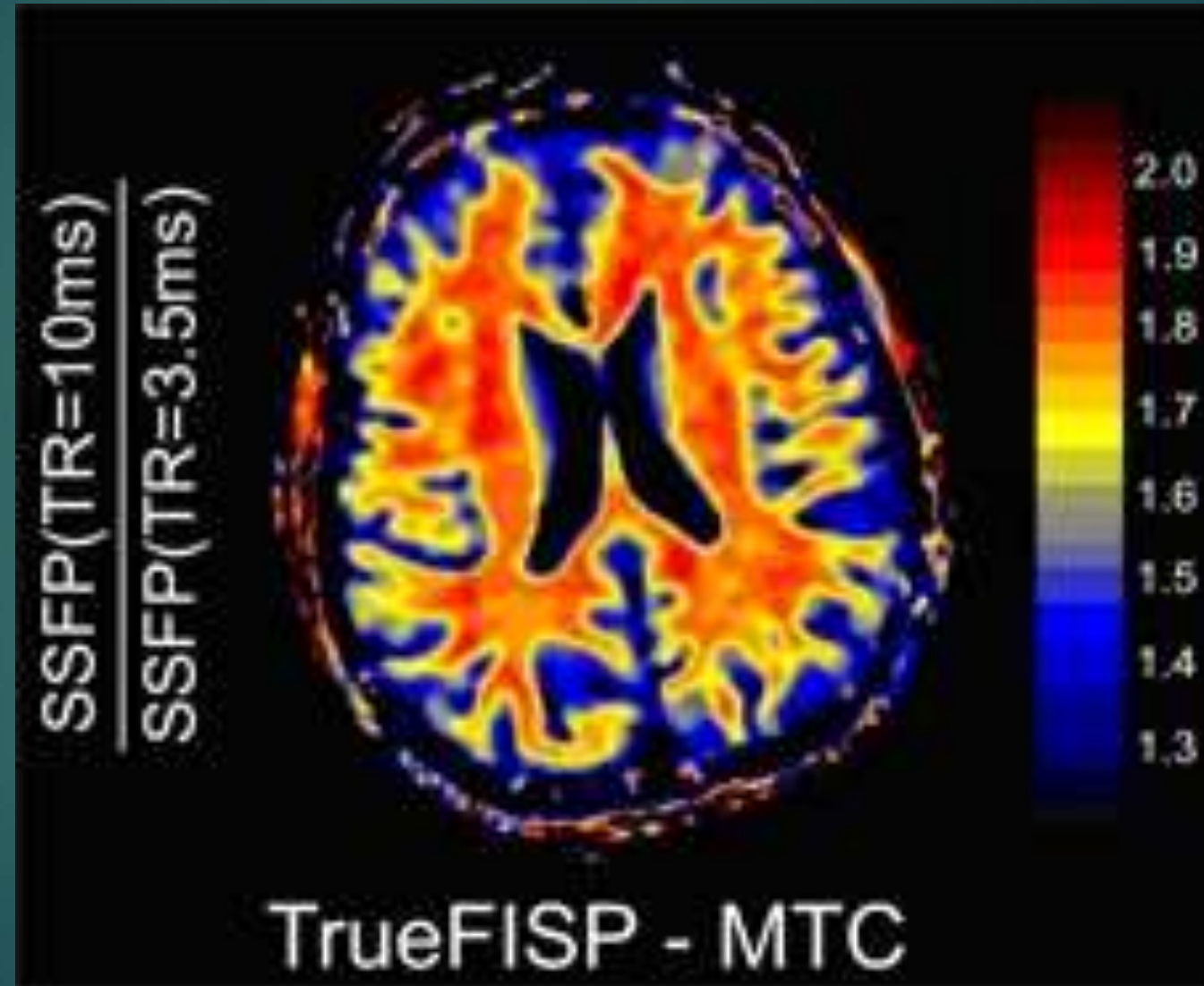
- ▶ WM: More signal on T2-weighted and less signal on T1-weighted images.
- ▶ As a result of the high sensitivity of T2-weighted spin-echo pulse sequences, MR images frequently reveal high-signal foci within the subcortical white matter.

## T2 and T1 in MS

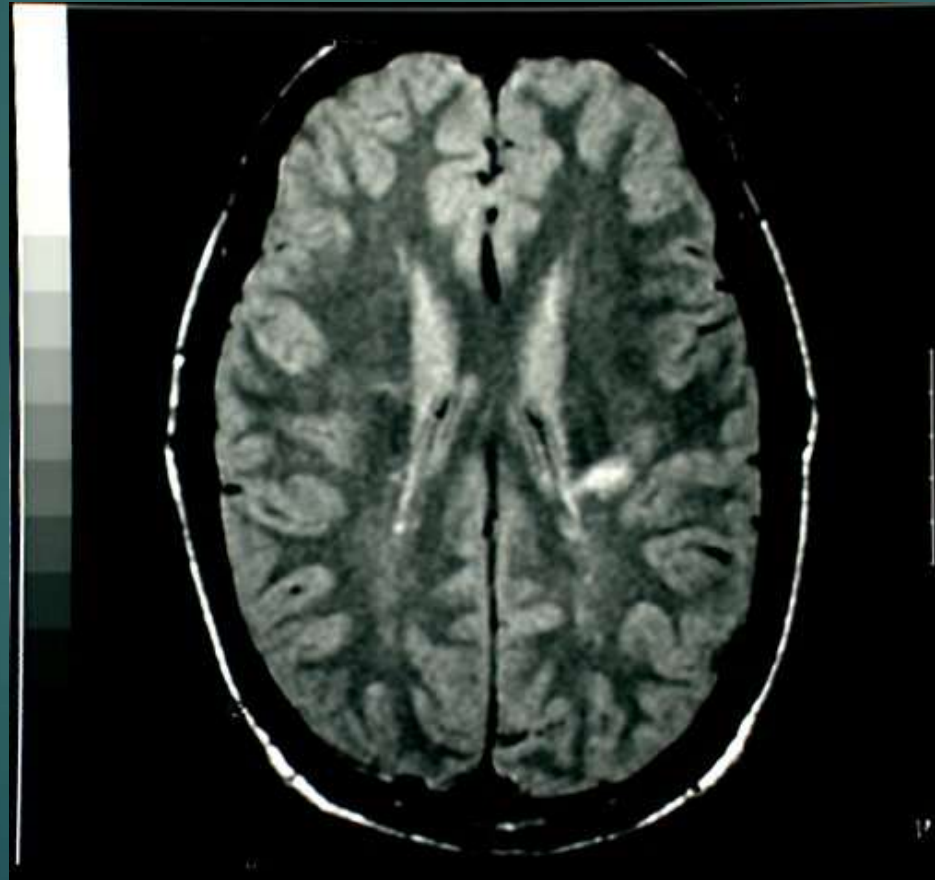


T2-weighted (A) and post-contrast T1-weighted (B) MR images. In A, many white-matter lesions are visible. Two of them are enhanced in B after the injection of gadolinium. This is a sign of increased blood-brain barrier permeability and continuing inflammation.

# Magnetization Transfer Imaging: better imaging of WM abnormalities

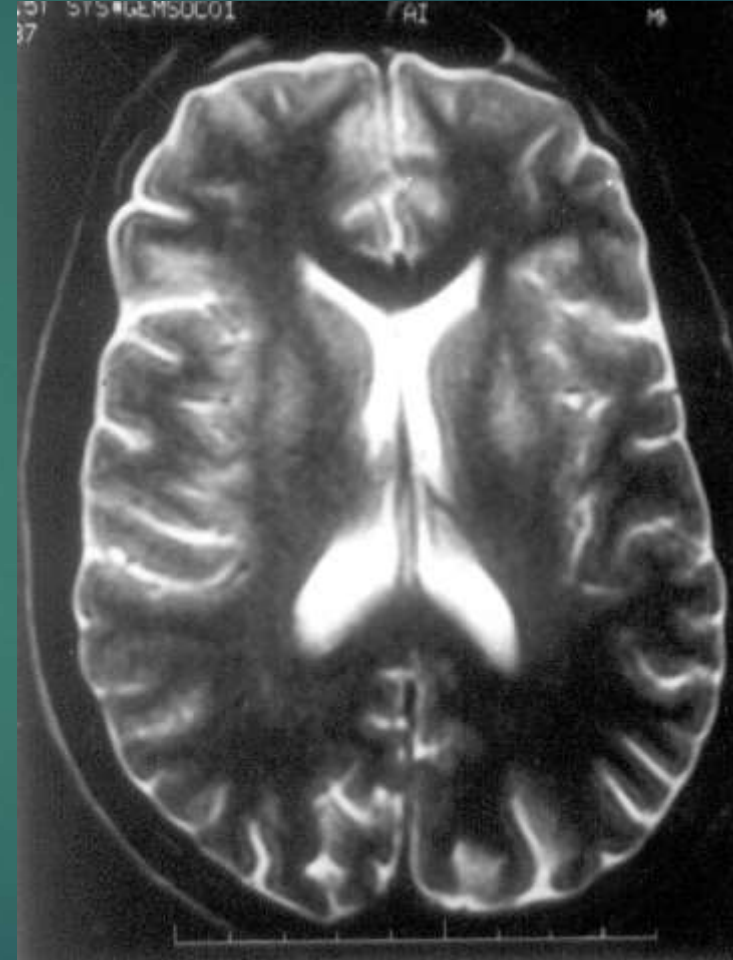
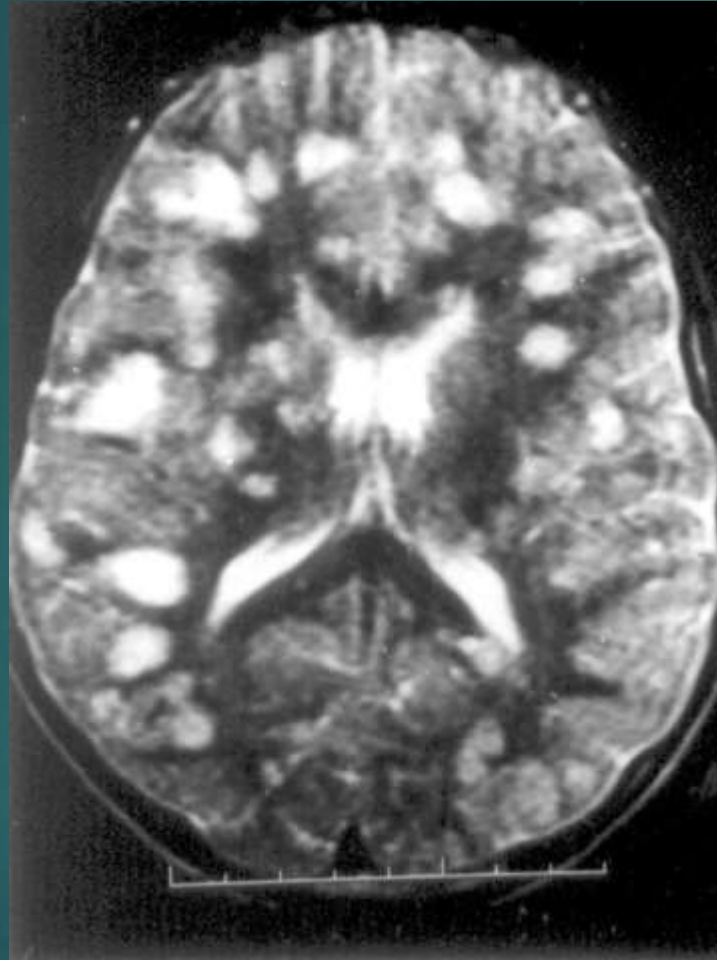


# White Matter: Lyme Disease



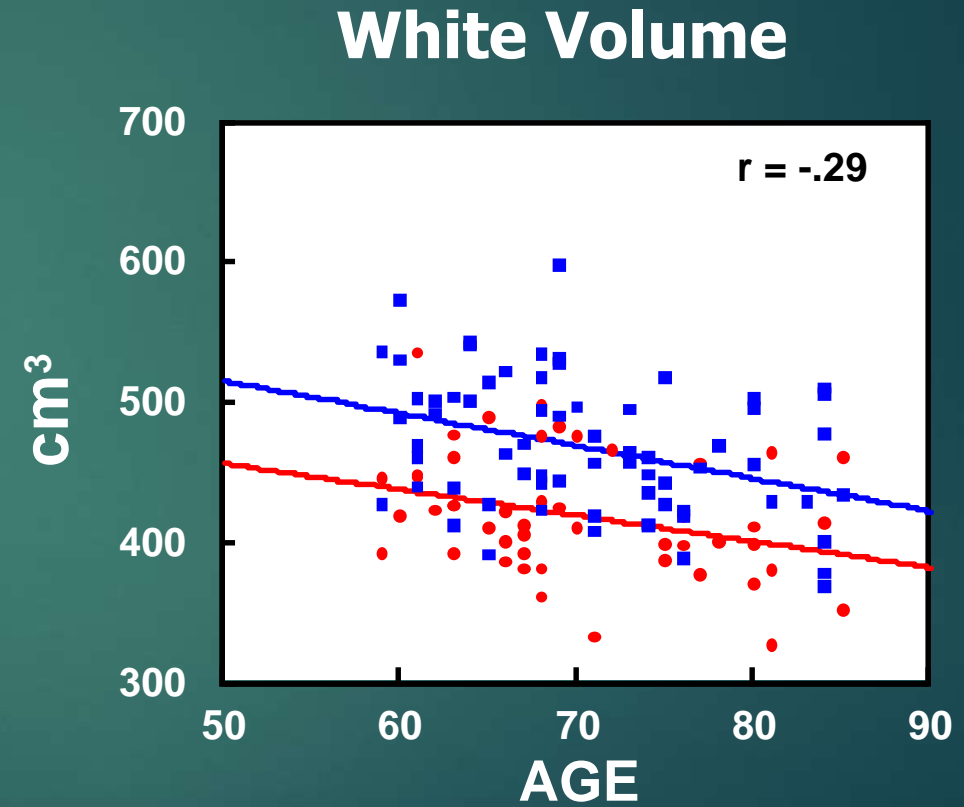
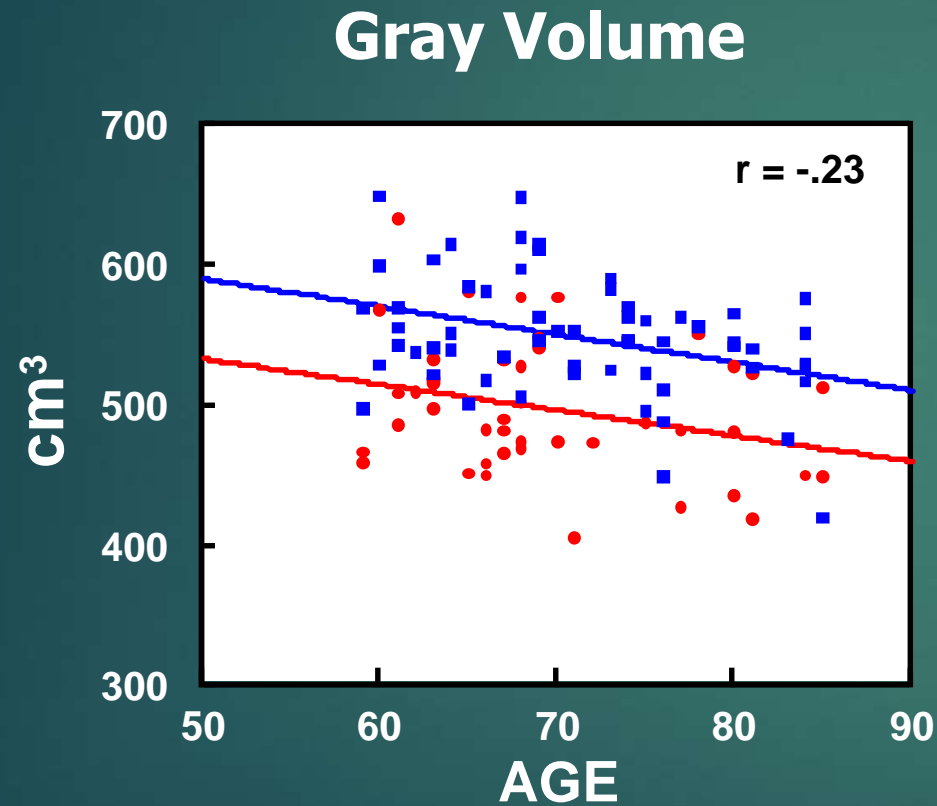


# MRI: demyelination in encephalomyelitis



Autoimmune Chronic Fatigue: Multiple hypertense lesions

# Both Gray and White Matter Volumes Are Negatively Correlated with Age



● WOMEN ■ MEN  
N = 116; Mean Age 70.4  
(7.5)

# Normal Aging 1

- ▶ Normal aging is not particularly associated with neuronal cell death, the observed relative decline in white matter may reflect faulty neural transmission efficiency and a decline in normal synaptic functioning.
- ▶ Age-related white matter changes may indicate a decline in interregional connectivity that could have secondary effects on gray matter structure and have obvious implications for maintenance of normal neuropsychological functioning in later life
- ▶ Cognitive changes in older individuals are causally related to degree of white matter change
- ▶ 30 to 80% of MRI scans done in persons over the age of 65 have changes in their cerebral white matter (Wong et al, 2002).

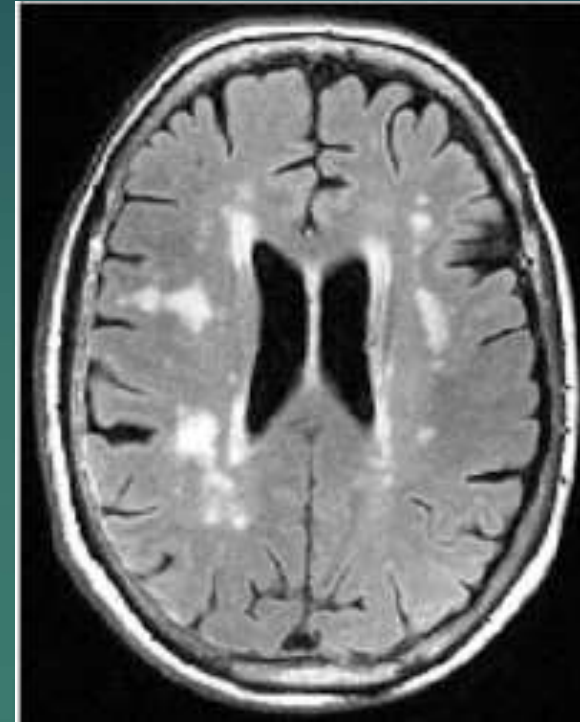
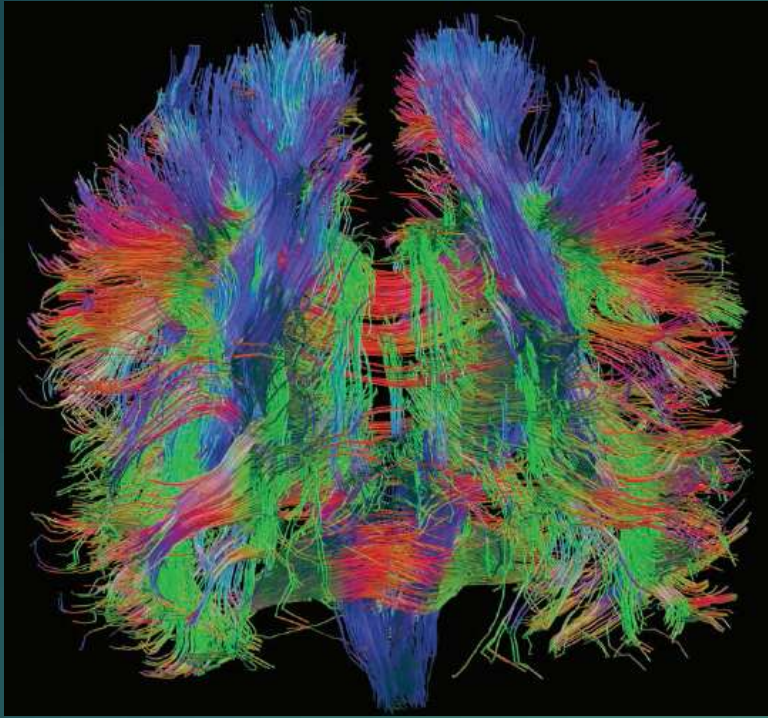
## Normal aging 2

- ▶ Age, anterior white matter volumes and performance on neuropsychological tests are significantly related
- ▶ Greater amounts of white matter are associated with better performance on neuropsychological tests
- ▶ Largest effect sizes are in the relationship between frontal white matter and tasks of learning/memory and executive functioning.

# Normal Aging 3

- ▶ 35% in 70's have abnormal WM (leukoaraiosis: greatest in periventricular, centrum semioval); small vessel ↓
- ▶ Cognitive Domains affected:
  - ▶ processing speed,
  - ▶ selective (not sustained) attention,
  - ▶ working memory,
  - ▶ executive functions,
  - ▶ discourse comprehension,
  - ▶ encoding/retrieval memory,
  - ▶ spatial rotation (but not IQ)





- ▶ Better neuronal wiring (white matter) in old age is linked to higher cognitive function
- ▶ 10% of differences depends on white matter integrity
- ▶ Hyperintensities closely linked to high levels of cortisol (stress)

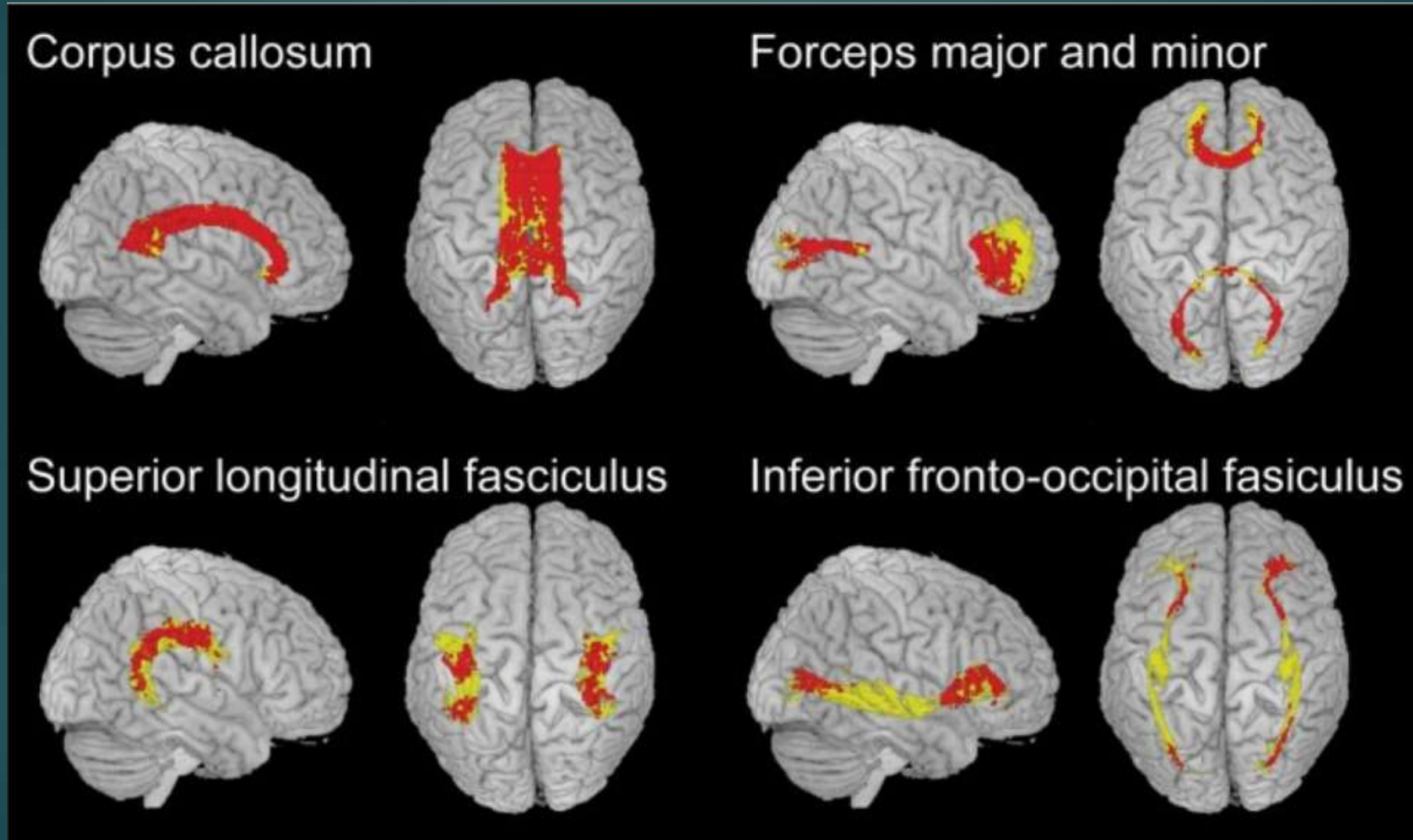
# Processing speed correlates with white matter integrity.

- ▶ Decline in processing speed is most prominent cognitive decline with normal aging (1 ½ s.d. decline).
- ▶ Fractional anisotropy values correlated negatively with reaction time in diffuse areas of frontal and parietal white matter, especially the anterior corpus callosum,
- ▶ The genu and body of the corpus callosum, superior longitudinal fasciculus, and inferior fronto-occipital fasciculus were among the areas most involved.
- ▶ Loss of white matter integrity mediates the relationship between age and cognitive processing speed.

# WM, IQ, & Math giftedness: Connectivity

- ▶ IQ shows a significant positive correlation with FA, mainly in the corpus callosum, supporting the idea that efficient information transfer between hemispheres is crucial for higher intellectual capabilities.
- ▶ Math-gifted adolescents show increased FA in white matter tracts connecting frontal lobes with basal ganglia and parietal regions.
- ▶ The enhanced anatomical connectivity observed in the forceps minor and splenium (both anterior frontal) may underlie the greater fluid reasoning, visuospatial working memory, and creative capabilities of these children.

# WM areas most related to Processing Speed



# Role of white matter in cognition and emotion

- ▶ Well-recognized sensorimotor deficits that can accompany white matter involvement – such as:
  - ▶ visual loss,
  - ▶ paresis,
  - ▶ spasticity,
  - ▶ ataxia,
  - ▶ gait disorder,
  - ▶ incontinence
- ▶ Wide variety of neurobehavioral dysfunction can occur, including focal disconnection syndromes, neuropsychiatric disorders including depression, and cognitive impairment often sufficiently severe to merit the term dementia (Filley, 2012).



# Neuropathological categories of white matter disorder

Genetic	Metabolic
Metachromatic leukodystrophy	Cobalamin (vitamin B <sub>12</sub> ) deficiency
Demyelinative	Vascular
Multiple sclerosis	Binswanger's disease
Infectious	Traumatic
HIV-associated dementia	Traumatic brain injury
Inflammatory	Neoplastic
Systemic lupus erythematosus	Gliomatosis cerebri
Toxic	Hydrocephalic
Toluene leukoencephalopathy	Normal pressure hydrocephalus

## Some conditions in which the normal-appearing white matter may be abnormal.

---

Metachromatic leukodystrophy	Leukoaraiosis
Phenylketonuria	Traumatic brain injury
Neurofibromatosis	Glioma
Tuberous sclerosis	Normal pressure hydrocephalus
Myotonic dystrophy	Aging
Fragile X tremor-ataxia syndrome	Autism
Multiple sclerosis	Attention deficits hyperactivity disorder
HIV infection	Aggression
Systemic lupus erythematosus	Bipolar disorder
Alcoholism	Schizophrenia
Hypoxia	Alzheimer's disease

---

# WM Lesion Distributions: Multifocal

- Multifocal examples
  - Small Vessel Ischemic Disease (SVID)
  - Multiple Sclerosis (MS)
  - Diffuse Axonal Injury (DAI)
  - Progressive Multifocal Leukoencephalopathy (PML)
- Confluent examples
  - Leukodystrophies in pediatric patient
  - Chemotherapy & radiation changes
- Selective examples
  - Central Pontine Myelinolysis (CPM)
  - Marchiafava-Bignami disease
  - Wallerian degeneration
  - Posterior Reversible Encephalopathy Syndrome (PRES)

# Classification of CNS demyelinating disorders

1. Primary demyelinating diseases: Multiple sclerosis (MS), Acute disseminated encephalomyelitis (ADEM), Acute hemorrhagic leukoencephalitis (AHL)
2. Secondary acquired demyelinating diseases: Central pontine myelinolysis (CPM), Progressive Multifocal Leukoencephalopathy (PML)
3. Leukodystrophies and metabolic disorders: sudanophilic leucodystrophy, metachromatic leucodystrophy, adrenoleucodystrophy, Krabbes leucodystrophy, Canavans disease
4. Toxic demyelination due to solvents: Hexachlorophane, cyanide, carbon monoxide, chronic solvent vapor abuse.

# Primary vs Secondary demyelinating diseases

## ▶ Primary:

- ▶ Damage to oligodendroglia & their myelin sheaths
- ▶ Axons are relatively preserved

## ▶ Secondary:

- ▶ Damaged axon → loss of myelin
- ▶ Axonal transection → Wallerian degeneration (axon degeneration) in distal portion
- ▶ But axonal loss clearly implies a worse prognosis than myelin damage alone



# Neurological Diseases that involve WM

- Normal aging brain
- Ischemic Vascular dementia
- Multiple Sclerosis
- TBI – Diffuse Axon Injury (DAI)
- Radiation effects on brain
- Infections: vasculitis, cerebritis
- HIV/AIDS
- Lyme Disease
- Alcoholism
- Neurotoxins
- Frontal Dementia
- NVLD
- Paranoid Psychosis
- Autism
- Sleep Apnea
- Guillain-Barré
- And 85 others

# Demyelinating Disorders 1

- ▶ Characterized by destruction of the myelin sheaths of the nerve
- ▶ In general: immune-mediated diseases, infection-mediated diseases, inherited disorders, & toxic disorders
- ▶ Often have variable course, ranging from mild & transient symptoms to severe, permanent, and fatal.
- ▶ Most common presenting complaints are rapid motor and sensory changes (paresis, visual loss, acute sensory loss)
- ▶ MS is the most common demyelinating condition

# Demyelinating Disorders 2

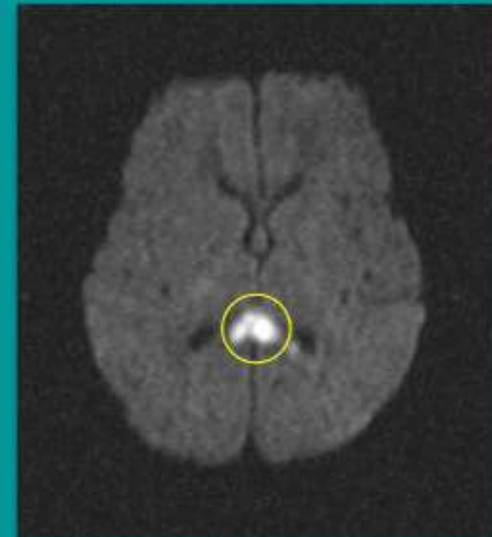
- ▶ All include cognitive decline
- ▶ Disorders that impair central impulse conduction produce slowed cognition— and cognitive slowing has become a distinctive feature of WMD
- ▶ Most common cognitive effect is slowed processing speed and attentional deficits which produce working memory impairment
- ▶ Focal & diffused deficits are not uncommon & can include retrieval memory deficit
- ▶ Cognitive deficits are associated with severity, duration, and recurrence of sxs
- ▶ Emotional reactions to physical sxs can be significant.

# Diffuse Axonal Injury (DAI in TBI)

- ▶ DAI as reactive axonal change
  - ▶ more swelling than tear
  - ▶ impaired transport not myelin damage
  - ▶ locus of cell injury enlarges
  - ▶ more distal axonal segments detach
  - ▶ evolves over 6-24 hours
- ▶ Mainly in white matter (CC, subcortical, brainstem), diffusely along path of trauma

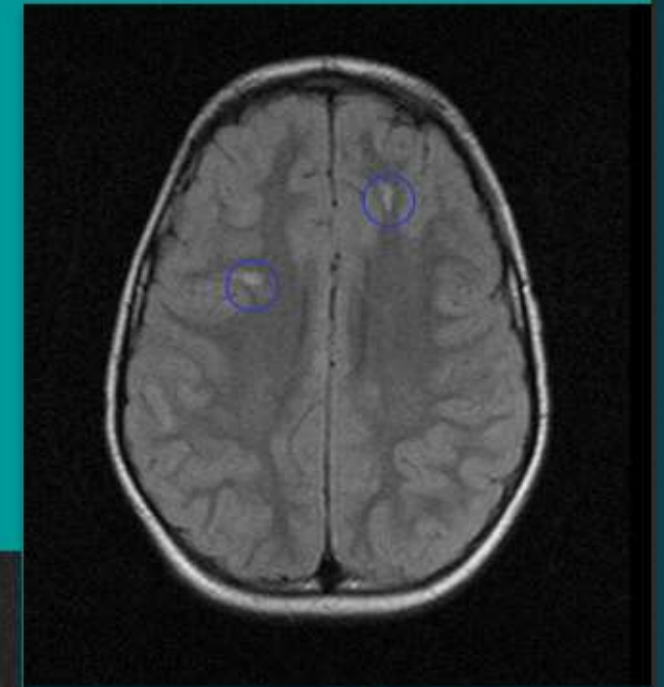
# DAI

- Associated with severe shear forces that occur with rapid deceleration
  - i.e. motor vehicle collisions
- Affects interfaces with disparate densities
  - GM/WM interfaces
- Graded by location
  - Frontotemporal
  - Corpus callosum
  - Brainstem
- May show restricted diffusion on DWI



Axial DWI MRI

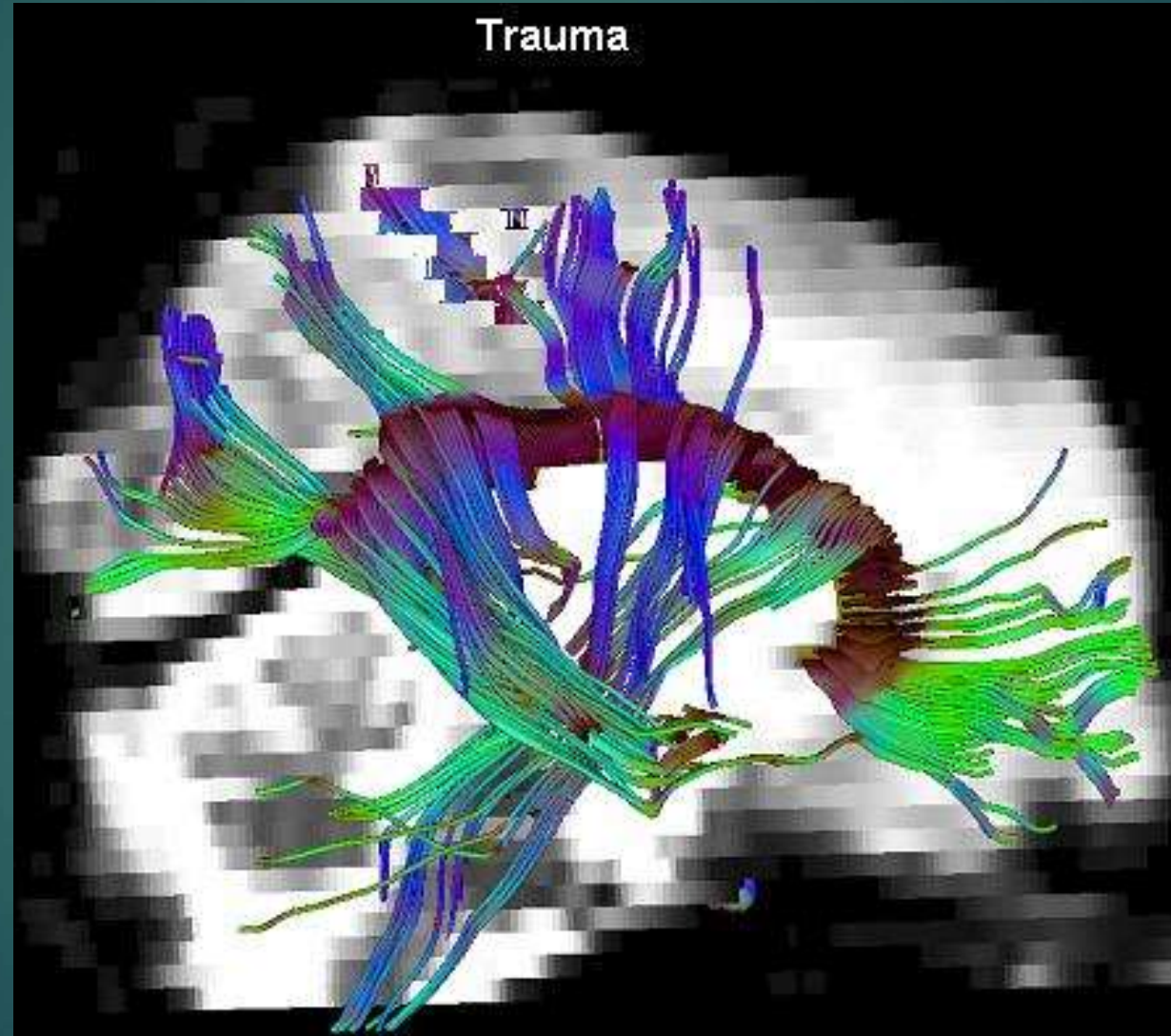
BIDMC PACS



Axial FLAIR MRI



# White Matter: Diffusion Tensor MRI of TBI



# Diffusion Tensor Imaging (DTI) in TBI

- ▶ Assess integrity of white matter tracts
- ▶ Note axonal swelling in (some) mTBI
- ▶ White matter changes noted on continuum, with TBI patients having poorer white matter integrity.
- ▶ An index of global white matter neuropathology was found related to cognitive functioning and predictive of cognitive deficits.

# DTI in mTBI

- ▶ Shenton et al completed a literature review of studies:
- ▶ Acute mTBI:
  - ▶ Differences in corpus callosum and internal capsule compared to controls – consistent with histopathology findings in mTBI
  - ▶ Frontal white matter (including dorsolateral PFC) correlated with worse EF in mTBI compared to controls
  - ▶ Mesencephalon abnormalities correlated with verbal memory

Shenton et al, 2012

# DTI in chronic mTBI

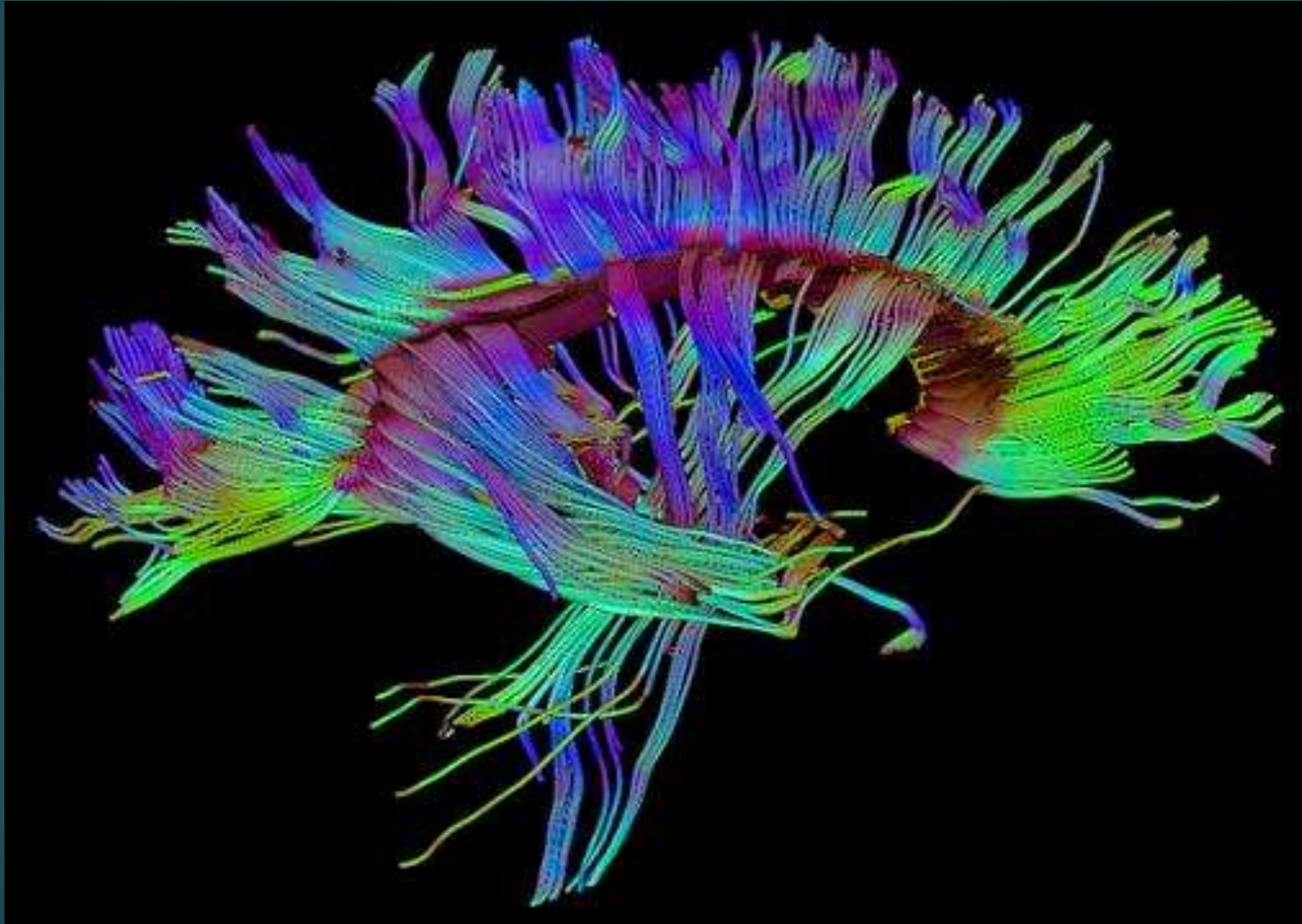
- ▶ Chronic mTBI:
  - ▶ Kraus et al suggested myelin damage is not present in mTBI, but is in moderate-severe TBI.
  - ▶ Diffuse axonal injury in TBI falls along spectrum depending on severity of TBI

# DTI in TBI

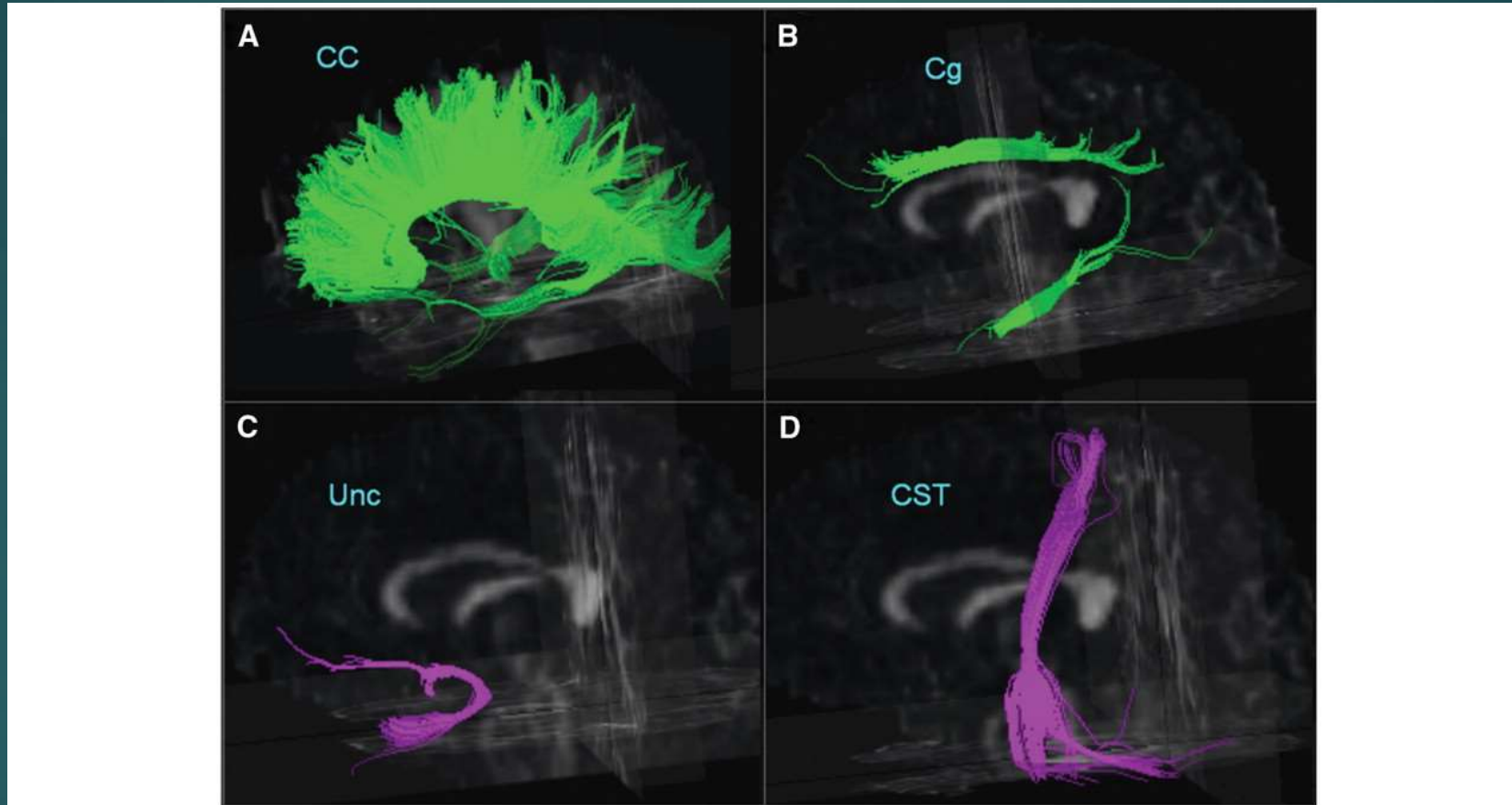
- ▶ Shenton et al suggest variability in DTI studies with mTBI related to different time periods, magnet strength, and region of focus in different studies.
- ▶ Differences in anatomical locations noting alterations
- ▶ HOWEVER, studies suggest radiological evidence that small and subtle brain injuries are present in mTBI



# White Matter: Diffusion Tensor MRI in major TBI



Fiber tracts of the corpus callosum (CC), cingulum (Cg), uncinate (Unc) and the corticospinal tract (CST) from a single subject superimposed on a 3-dimensional FA image.



Zhang, Y. et al. *Brain* 2009 132:2579-2592; doi:10.1093/brain/awp071

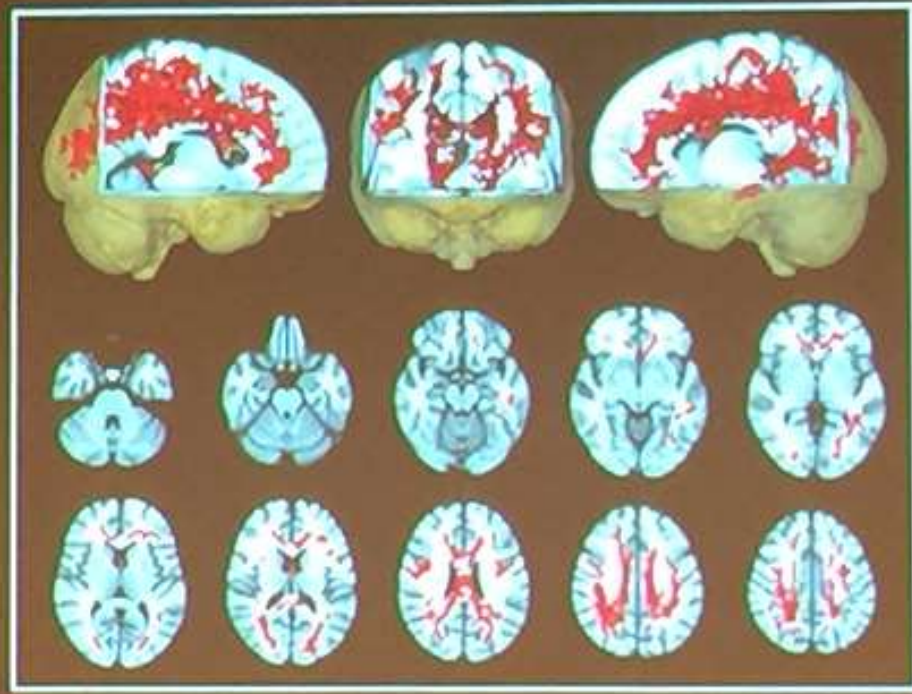
Copyright restrictions may apply.

# Chronic Traumatic Encephalopathy (CTE): WM injury significant

## MRI: White Matter Injury

**Diffusion Tensor Imaging  
(MRI measure of white  
matter integrity)**

**Retired NFL players with  
cognitive impairment or  
depression vs. normal  
controls**

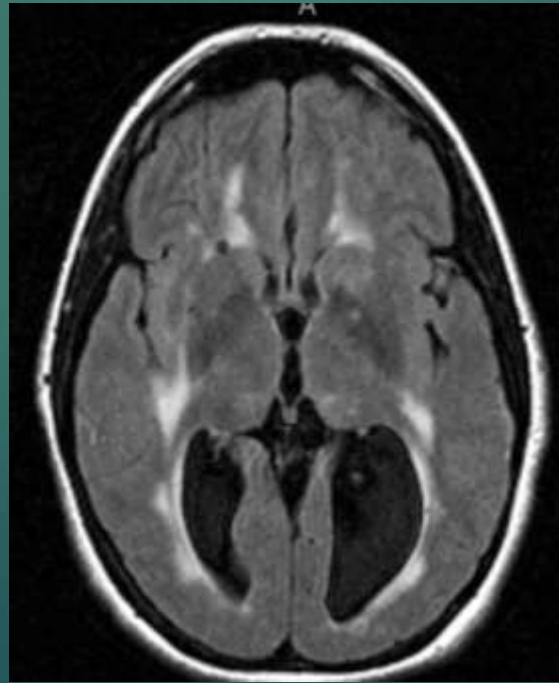
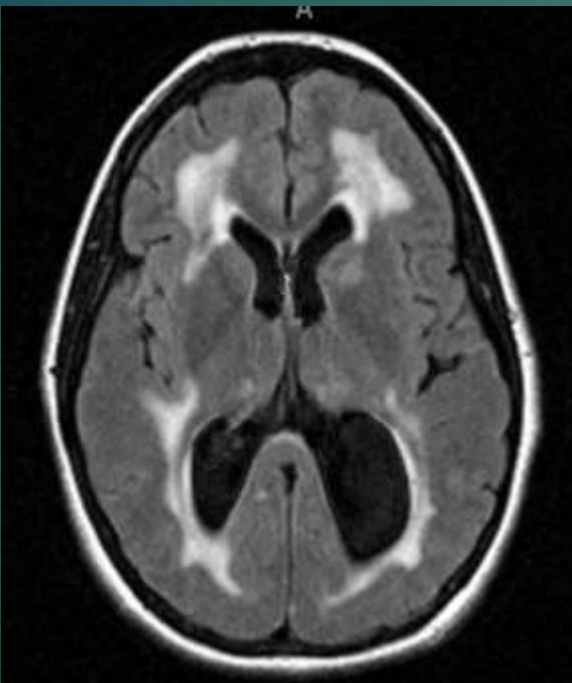
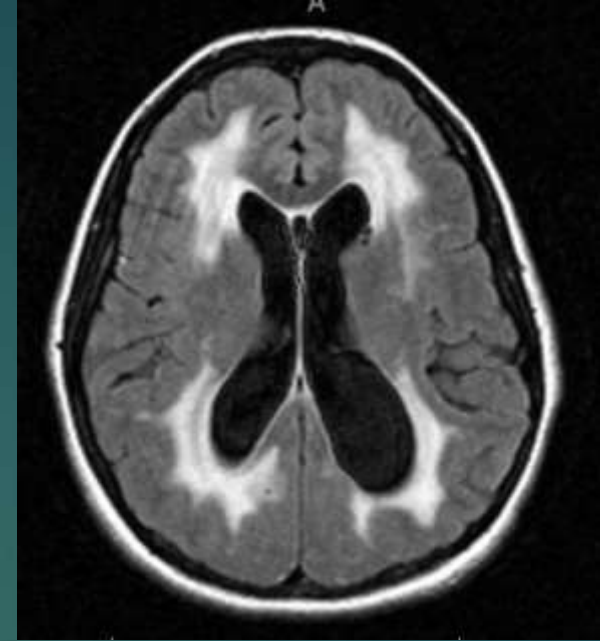
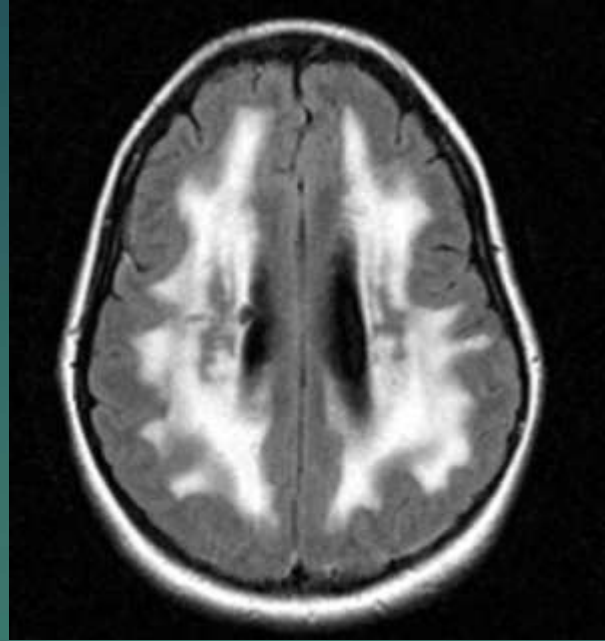
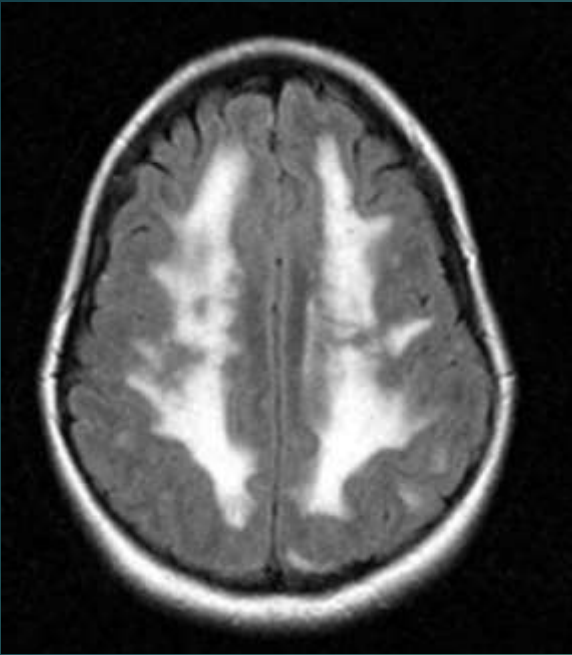


**Haet et al. JAMA Neurol 2013**

# CADASIL

- ▶ Cerebral autosomal dominant arteriopathy subcortical infarcts and leukoencephalopathy (CADASIL)
- ▶ Autosomal dominant disease – mutation in NOTCH3 gene
- ▶ Diffuse white matter hyperintensities
- ▶ Hyperintense lacunar infarctions in basal ganglia and subcortical location
- ▶ Average age of presentation: 25 – 30 years, earlier onset in women

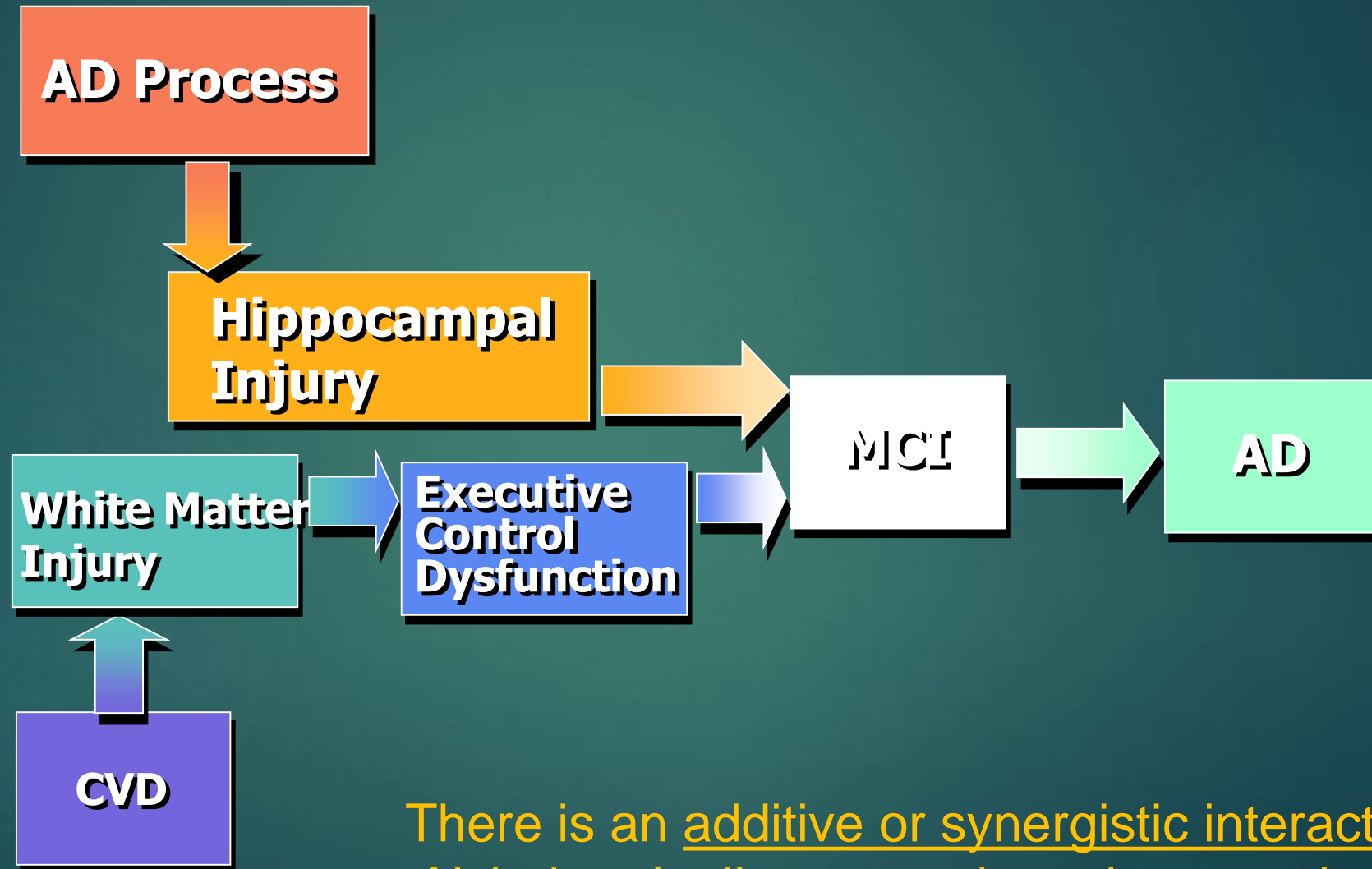




Diffuse white matter FLAIR  
signal abnormalities with  
significant volume loss.

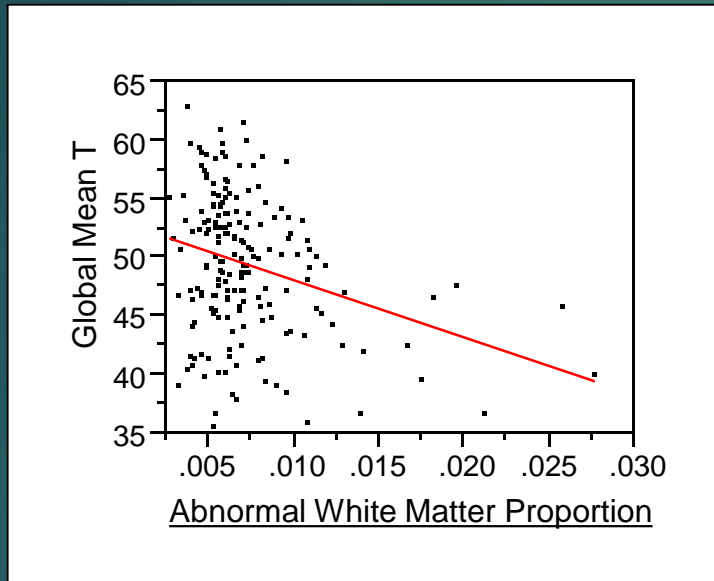


# Combined Role of AD and CVD in MCI and Dementia Risk

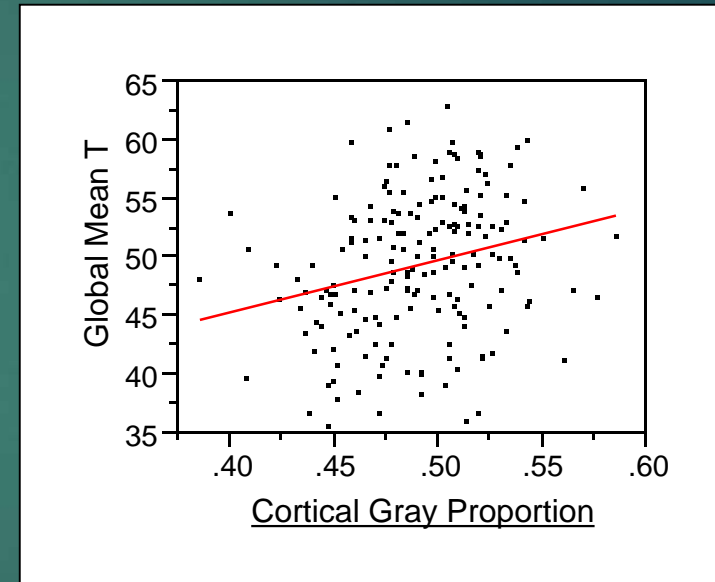


There is an additive or synergistic interaction between Alzheimer's disease and cerebrovascular pathologies

# White Matter Damage and Cortical Volume *Independently* Predict Cognitive Performance



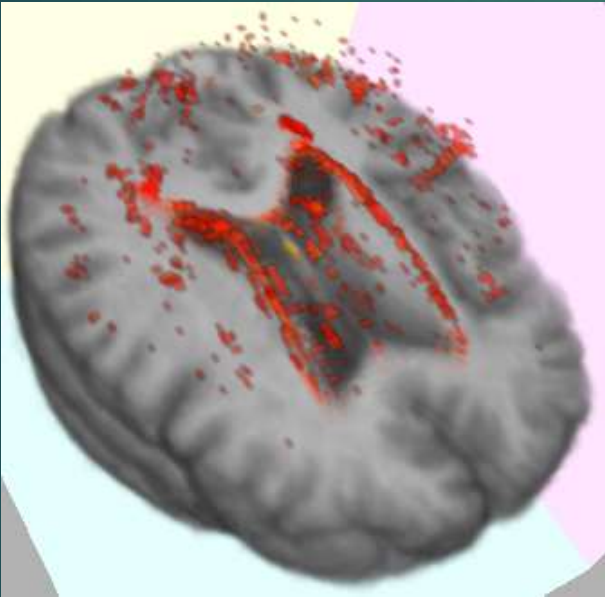
$t = -4.1, p < .0001$



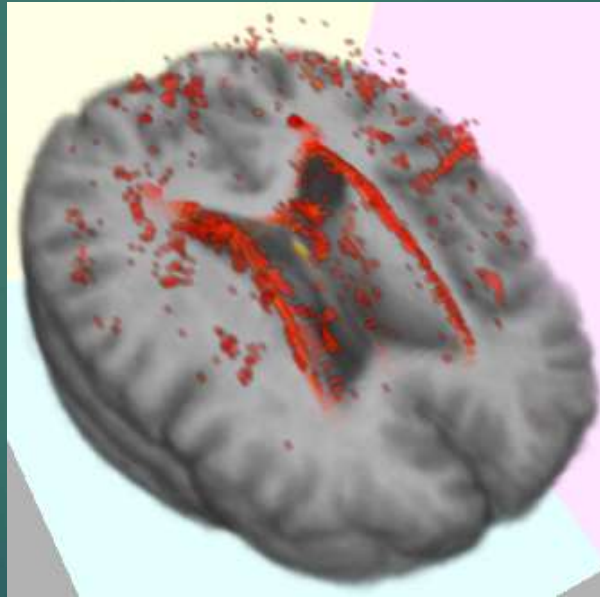
$t = 3.6, p = .0004$

# Baseline White Matter Hyperintensities (WMH) Burden in ADNI

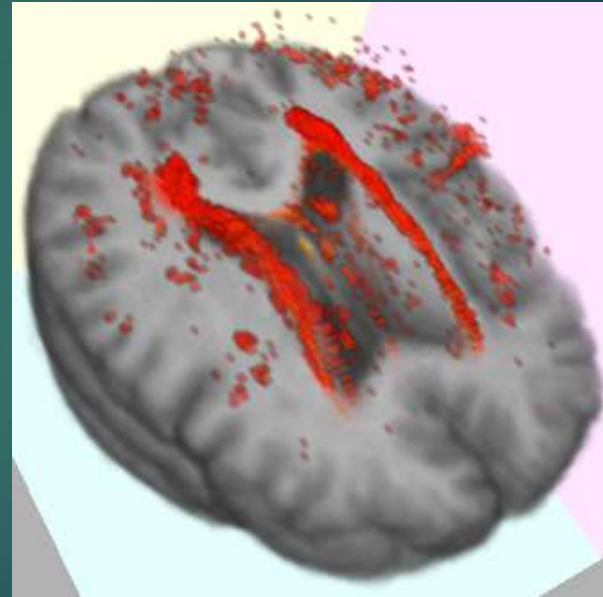
- Longitudinal Changes In White Matter Disease and Cognition in the First Year of the Alzheimer's Disease Neuroimaging Initiative
- ADNI subjects had WMH burden at baseline that is comparable to that of population-based studies
- Normal and MCI had similar WMH distributions; increased WMH burden in AD with suggestions of anterior-posterior progression



Normal



MCI



AD

# ADNI: WMH volume increase correlates with cognitive decline

- ▶ AD was associated with significantly greater baseline WMH and rate of WMH accretion was lowest for normal and highest for AD
- ▶ Vascular risk was significantly associated with baseline WMH and increase in WMH
- ▶ Change in WMH volume was significantly associated with worsening scores in MMSE and ADAS-Cog independent of:
  - ▶ Age
  - ▶ ApoE4
  - ▶ Vascular risk
  - ▶ Diagnosis

# MRI: Leukoaraiosis

- ▶ **Leukoaraiosis**, a small vessel disease, refers to the appearance on CT or MRI scans of damage in the white matter regions of the brain.
- ▶ **Leukoaraiosis** is a common finding in stroke patients. **Leukoaraiosis** appears to be an independent predictor of stroke outcomes.
- ▶ Diffuse UBOs in periventricular, centrum semiovale, and subcortical areas
- ▶ Leukoaraiosis: patchy or diffuse WM hyperintensities on T2
- ▶ Normal leukoaraiosis: pencil-thin line periventricularly, rounded foci at angles of frontal or occipital horns
- ▶ Pathological leukoaraiosis: intense halo periventricularly, patchy distribution, irregular margins, bilateral; lesions >2x2mm

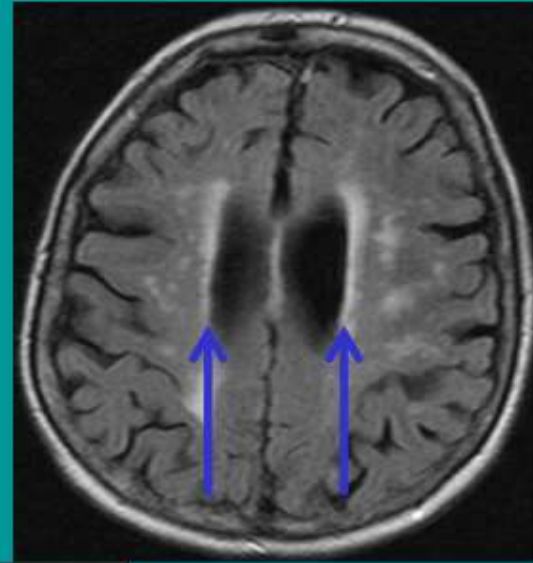


# Ischemic Vascular Dementia (IVD):

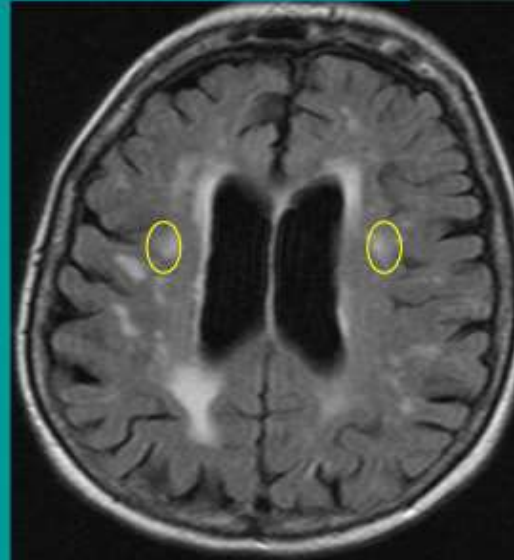
- ▶ Leukoencephalopathy: gradual ischemic vascular damage to cortical white matter
- ▶ Leukoaraiosis: severity of impairment related to the amount of WM tissue loss
- ▶ Cognitive: decreased processing speed, retrieval failure after interference but not delay, decrease in semantic access, set shifting impaired, spatial rotation impaired

# SVID: Subcortical Vascular Ischemic Disease

- Risk factors similar to those of cardiovascular (CV) disease
- Locations
  - **Periventricular**: associated with age
  - **Deep**: associated with other CV risk factors
  - Subcortical WM: common in women
- Associations
  - Cognitive decline
  - Dementia
  - Gait disturbances
  - Stroke
  - Mortality



Axial FLAIR MRI



Axial FLAIR MRI

BIDMC PACS

# Neuropathological Subtypes

**Small Vessel Disease** – Most common cause of Vascular Cognitive Impairment

- ▶ Leukoaraiosis
- ▶ Subcortical infarcts

# Neuropathological Subtypes

## ▶ Leukoaraiosis (Small Vessel Disease)

- ▶ Describes diffuse, punctate, or confluent white matter abnormalities
- ▶ MRI (hyperintensity of white matter), CT (hypodense)
- ▶ Occurs with infarcts, leukodystrophies, metastases, inflammatory condition
- ▶ Detected in most older adults
- ▶ No distinct cognitive profile
- ▶ White matter changes associated with
  - ▶ Increased risk of stroke
  - ▶ Dementia

# Neuropathological Subtypes

- ▶ Leukoaraiosis (continued)
  - ▶ Small amounts of white matter abnormalities
    - ▶ Memory/language impairment some patients
  - ▶ Large amounts
    - ▶ Cognitive impairment • Motor deficits
    - ▶ Personality change • Urinary incontinence
    - ▶ Gait disturbance
  - ▶ In deep white matter
    - ▶ Executive impairment
    - ▶ Slowed processing speed
    - ▶ Working memory
    - ▶ Visuo-spatial abnormalities



# Neuropathological Subtypes

## ► Sub-cortical Ischemic Vascular Disease (SIVD)

Occurs through...

- Small vessel infarct
- Ischemia
- Incomplete ischemia

Within...

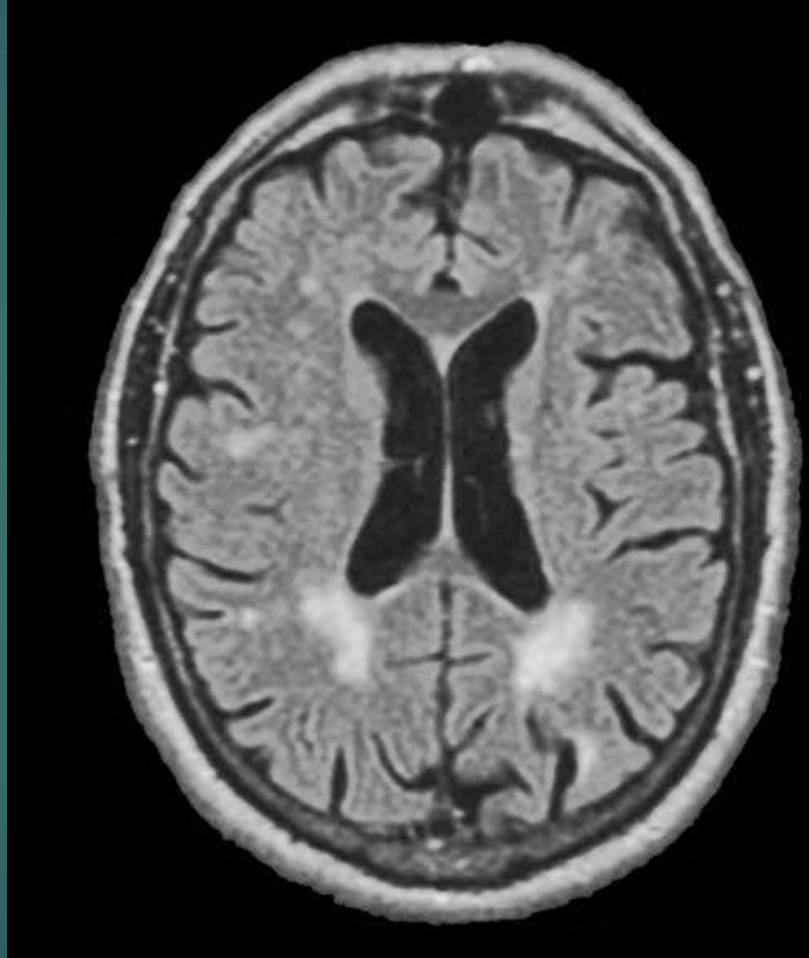
- Cerebral white matter
- Basal Ganglia
- Brainstem
- Prefrontal subcortical circuit
- Thalamo-cortical circuit

# Neuropathological Subtypes

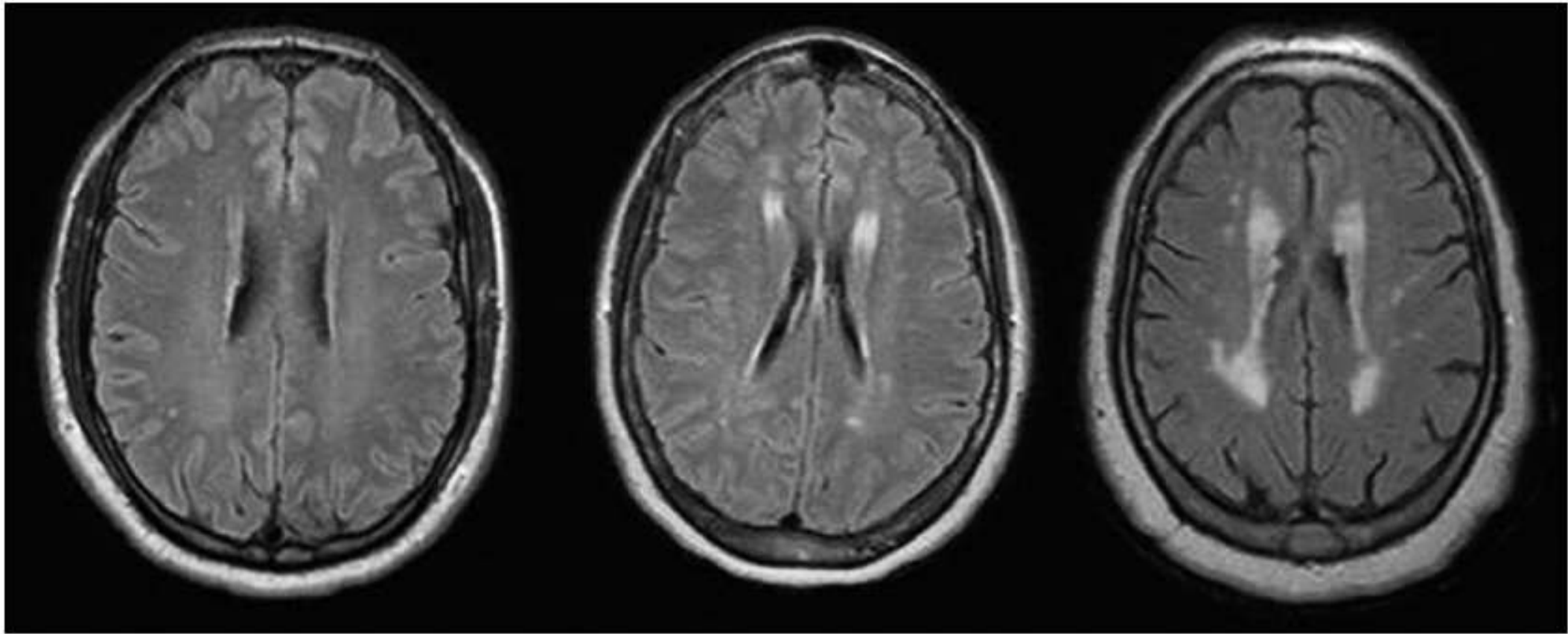
- ▶ Pattern lesions associated with clinical syndrome
  - ▶ Pre-frontal subcortical circuit (pre-frontal cortex, caudate, pallidum, and thalamus) or Thalamo-cortical circuit
  - ▶ “subcortical syndrome” → “dysexecutive” syndrome
    - ▶ Deficits in ability to plan, organize, initiate, and shift between tasks
- ▶ Three distinct frontal lobe syndromes
  - ▶ Dorsolateral (executive functions and impaired recall)
  - ▶ Orbitofrontal (behavior, emotional changes)
  - ▶ Anterior cingulate (abulia, akinetic mutism)

# Periventricular white matter lesions

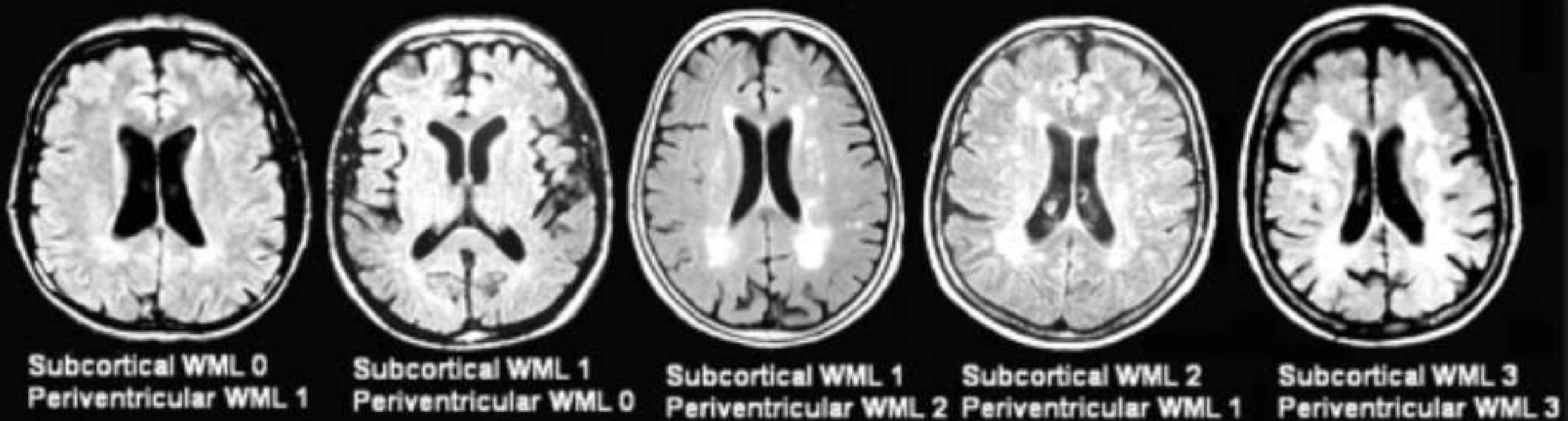
Periventricular:  
immediately to the  
side of the two  
lateral ventricles



Most common cause of periventricular white matter changes is normal aging  
(that is not associated with a disease process?)



Mild, Moderate, Severe Periventricular WMH



(1) Periventricular hyperintensity

0 = absence

1 = "caps" or pencil-thin lining

2 = smooth "halo"

3 = irregular PVH extending into the deep white matter

(2) Deep white matter hyperintense signal

0 = absence

1 = punctuate foci

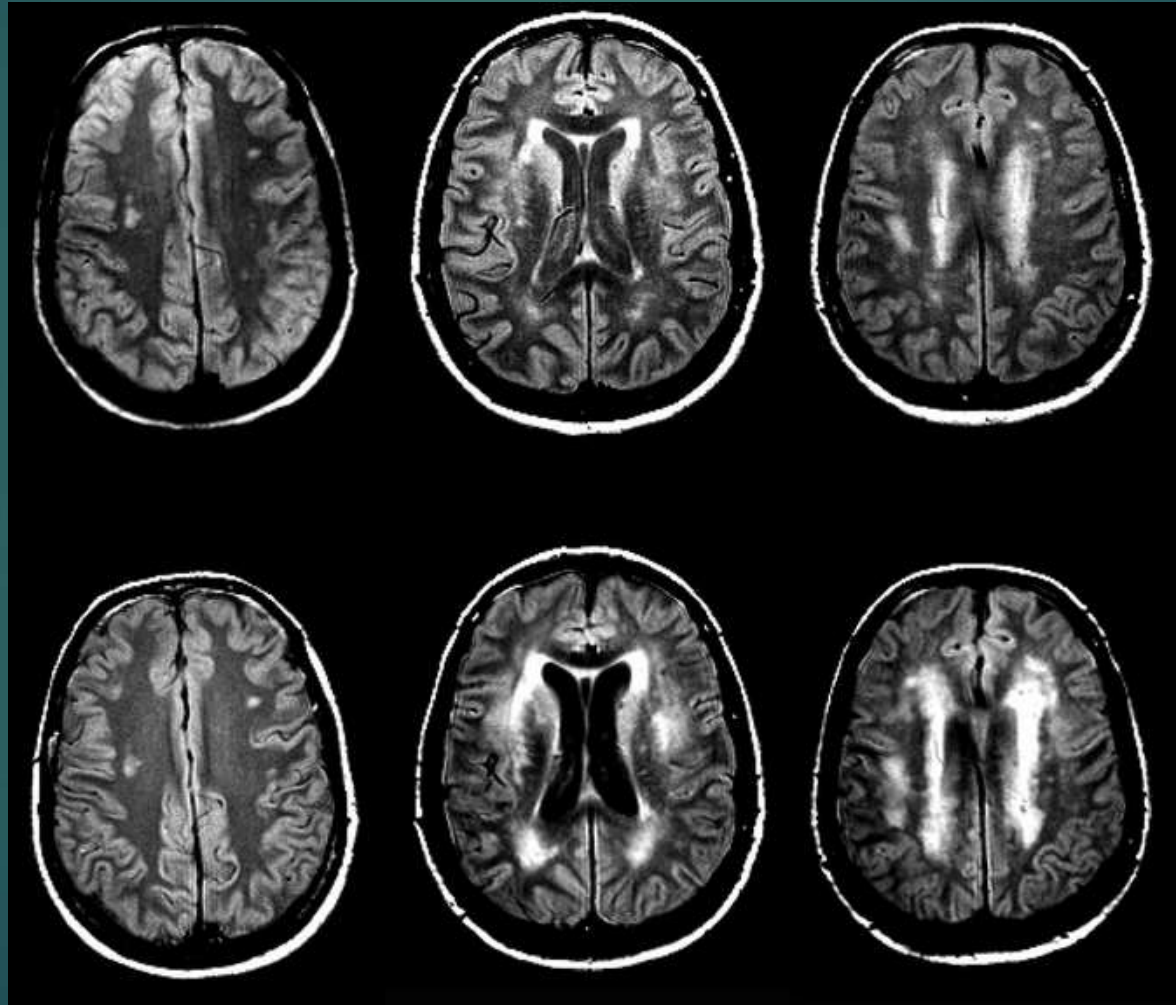
2 = beginning confluence of foci

3 = large confluent areas



# Progression of leukoaraiosis

Baseline

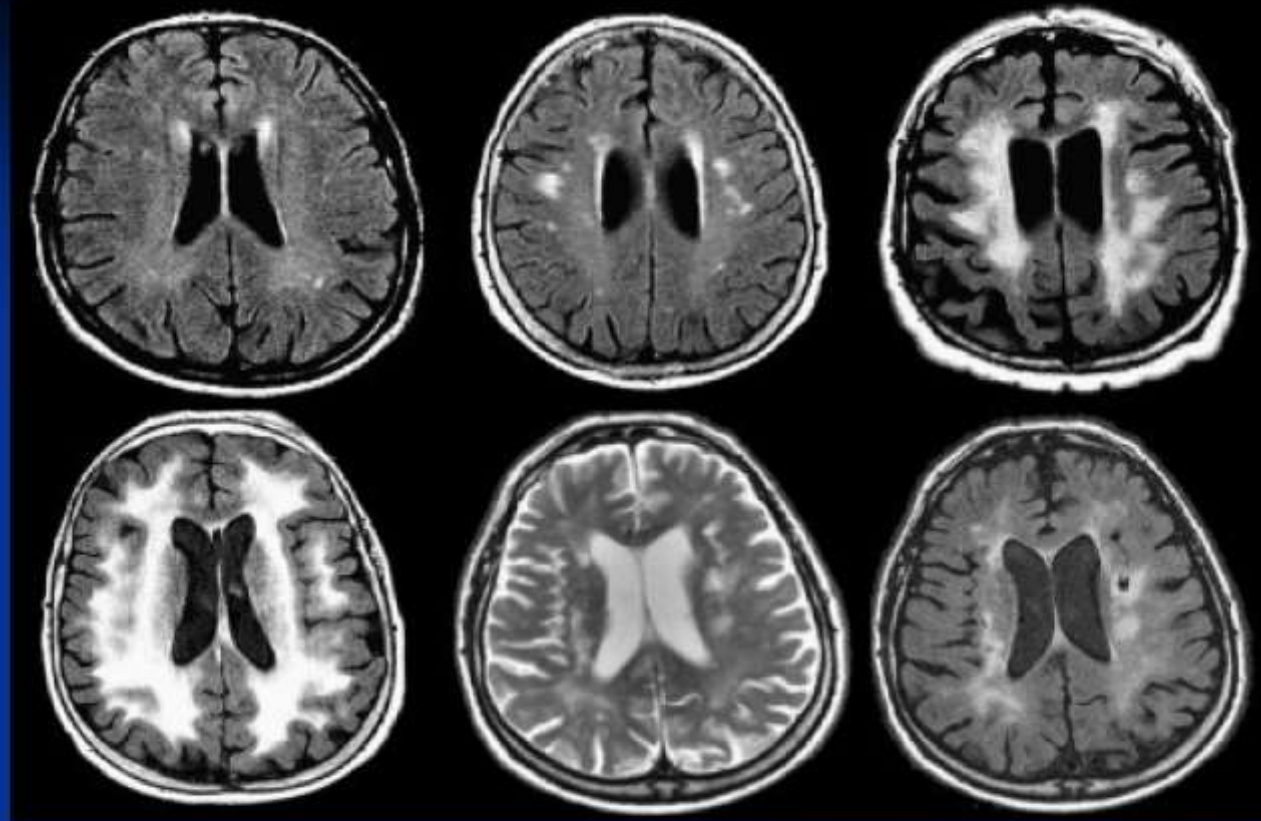


6 Years later

# Spectrum of Small Vessel Disease

Punctate  
foci

Severely  
abnormal



Lacunar  
infarcts

The spectrum of small vessel disease–related brain changes in MRI: white matter lesions ranging from punctate foci (*upper left*) to extensive confluent abnormalities (*lower left*) and lacunar infarcts (*lower right*).

## Leukoaraiosis: white matter change due to aging

- ▶ Areas of white matter hyperintensity are seen with increasing frequency in later decades.
- ▶ Changes greatest in periventricular area, centrum semiovale, and subcortical white matter
- ▶ Mechanisms: glial cell loss, small vessel infarcts, arteriosclerosis, infection

# Leukoaraiosis & brain activation

- ▶ Leukoaraiosis, (also called small vessel ischemia) and often referred to as unidentified bright objects or "UBOs" on brain scans
- ▶ Diseased blood vessels leads to small areas of damage in the white matter of the brain.
- ▶ Aging and high blood pressure are risk factors for leukoaraiosis
- ▶ Affects language processing during the semantic decision task and visual perception.
- ▶ Leukoaraiosis is not a benign manifestation of aging but an important pathologic condition that alters brain function

## Leukoaraiosis 2

- ▶ Patients with significant leukoaraiosis have a poor prognosis in terms of death, stroke, and myocardial infarction
- ▶ Leukoaraiosis is an independent and strong predictor of dementia in stroke patients
- ▶ Presence of leukoaraiosis increases the risk of intracranial bleeding in patients with cerebrovascular diseases treated with anticoagulants.



# Periventricular White Matter: PVM

- ▶ Individuals with PVM lesions perform nearly 1 standard deviation below average on tasks involving processing speed.
- ▶
- ▶ WM lesions strongly correlate with
  - ▶ reduced gait speed
  - ▶ reduced mental ability

(Starr et al, 2003; Guttman et al, 2000; Whitman et al, 2001).

# WM Hyperintensities

- ▶ White matter hyperintensities predict an increased risk of stroke, dementia, and death.
- ▶ Therefore white matter hyperintensities indicate an increased risk of cerebrovascular disease.
- ▶ In the general population the prevalence of white matter hyperintensities ranges from:
  - ▶ 11-21% in adults aged around 64
  - ▶ 94% at age 82.
  - ▶ Heritability is high, 55-73%.
- ▶ Pathological findings in regions of white matter hyperintensity include myelin pallor, tissue rarefaction associated with loss of myelin and axons, and mild gliosis.

# WM Hyperintensities

- ▶ These lesions are located in the deep white matter, typically sparing subcortical U-fibers, and are often seen together with vessels affected by small vessel disease.
- ▶ The affected vessels are presumed to induce the lesions in deep white matter through:
  - ▶ chronic hypoperfusion of the white matter
  - ▶ disruption of the blood-brain barrier,
  - ▶ leading to chronic leakage of plasma into the white matter.
- ▶ More common and extensive in patients with cardiovascular risk factors and symptomatic cerebrovascular disease
- ▶ Neuropathological studies: WM hyperintensities usually represent pathological small vessel disease

# Meta-analysis of WM Hyperintensities

- ▶ Important indicators of future risk of disease, being associated with an increased risk of stroke, faster cognitive decline (especially in the executive function and processing speed domains), dementia, and death.
- ▶ If found, doctors should do detailed screening for risk factors for stroke and dementia
- ▶ More aggressive antihypertensive treatment is associated with reduced WM progression in patients after stroke, as well as with a reduction in stroke itself

# White Matter Changes Predict Dementia Risk

- ▶ Subjects with fastest rate of growth in WM hyperintensities, were more likely to later develop permanent thinking problems that in many cases led to dementia than those with a slow rate of growth in these types of brain lesions.
- ▶ Every cubic centimeter (less than a quarter of a teaspoon) increase in the amount of brain lesions was associated with a 94 percent increased risk of developing cognitive impairment.



# Frontal Dementia

- ▶ Human Brain: most frontal white matter interconnections of any primate
- ▶ FTD and Alzheimer's disease are each associated with a characteristic distribution of white matter degradation.
- ▶ There is a greater vulnerability of white matter in FTD than in Alzheimer's disease.

## Core distinctions between cortical, white matter, and subcortical dementia.

Domain	Cortical	White Matter	Subcortical
Declarative Memory	Encoding deficit	Retrieval deficit	Retrieval deficit
Procedural Memory	Normal	Normal	Impaired
Language	Impaired	Normal	Normal

## Mild cognitive dysfunction compared with mild cognitive impairment.

<b>Mild Cognitive Dysfunction</b>	<b>Mild Cognitive Impairment</b>
White matter involvement	Gray matter involvement
One type	Multiple types
Clinically and radiologically defined	Clinically defined
Frontal white matter localization	Hippocampus putative site for amnestic MCI
Neuroimaging biomarkers available	Biomarkers not firmly established
Myelin damage with or without axonal loss	Synapse and cell body loss
Applicable to any age	Applicable only to aging
Relevant to all white matter disorders	Relevant to neurodegenerative disease
Treatment of disorder may be effective	No treatment known to be effective

## The profile of white matter dementia.

---

Cognitive slowing

Executive dysfunction

Sustained attention deficit

Memory retrieval deficit

Visuospatial impairment

Psychiatric disorder

Relatively preserved language

Normal extrapyramidal function

Normal procedural memory

---

# WM dementia

- ▶ Language is typically normal or nearly so in affected patients,
- ▶ Deficits are more apparent in cognitive speed, executive function, and attention.
- ▶ The relative subtlety of these deficits can mean that many impaired patients remain undetected as other sensorimotor features of the illness often dominate the clinical encounter.



# Short MS measures

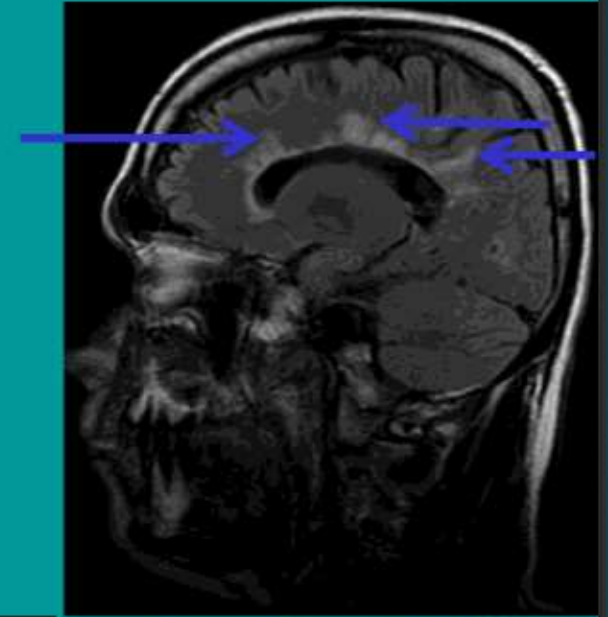
- ▶ MMSE is too language based.
- ▶ More useful tests include:
  - ▶ Montreal Cognitive Assessment (MoCA; Nasreddine et al., 2005),
  - ▶ Frontal Assessment Battery (FAB; Dubois et al., 2000),
  - ▶ Clock Drawing Test (CDT; Cosentino et al., 2004).
  - ▶ The MoCA (Griebe et al., 2011), the FAB (Kanno et al., 2011), and the CDT (Kim et al., 2009) have all been found sensitive to white matter dysfunction in various disorders.
  - ▶ MoCA may be most convenient of these measures; has memory retrieval, a clinical feature central to the assessment of WMD

# Migraine

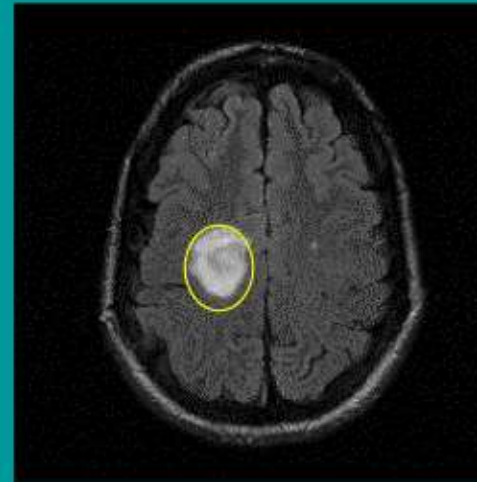
- ▶ Periventricular WM changes are often an accompaniment of migraine, and occur in roughly 20% of persons with migraine.
- ▶ As about 10% of the population has migraine, this means that about 2% of the population has white matter lesions due to migraine.

# MS

- Autoimmune demyelinating disease
- Most common in middle-aged females
- Sagittal FLAIR images useful to evaluate
  - lesions within the corpus callosum
  - Dawson's Fingers
- Often enhancement acutely
- Multiple subtypes/variants
  - i.e. Balo's concentric sclerosis
- Head MRI
  - 80 % sensitive & 90 % specific
- McDonald's criteria
  - 2 MRI lesions
  - 2 clinical episodes



Sagittal FLAIR MRI



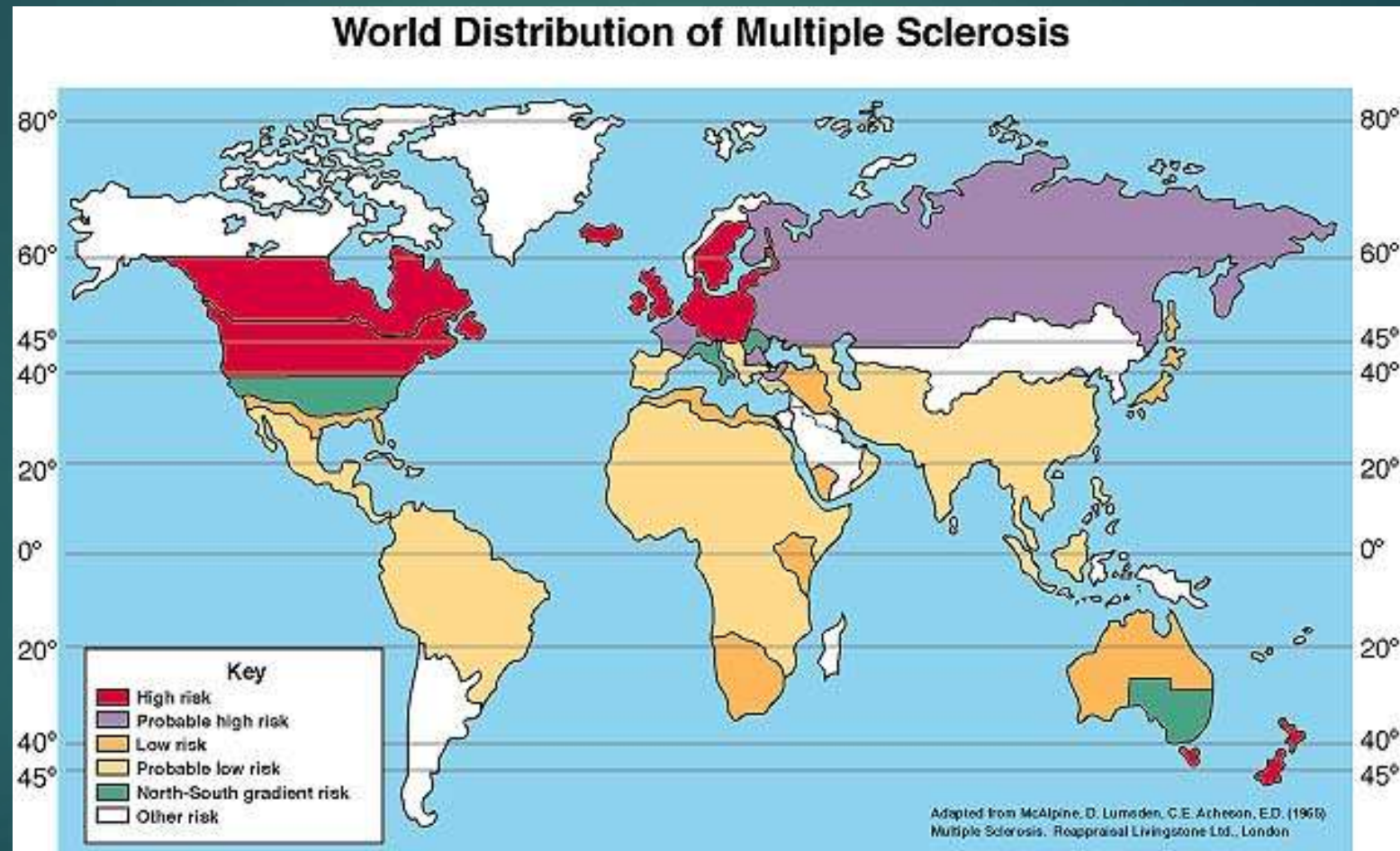
Axial FLAIR MRI

BIDMC PACS

# Multiple Sclerosis is both a White Matter & a Grey Matter Disease

- ▶ Degeneration of gray matter is increasingly recognized as the primary contributor to progressive cognitive decline in MS.
- ▶ MS is both a neurodegenerative and inflammatory demyelinating disease
- ▶ A slow loss of dendritic density as demonstrated by gray matter atrophy, due to ongoing neurodegenerative processes, is the more likely explanation of cognitive impairment in MS patients
- ▶ But white matter is involved in many of other symptoms

# Multiple Sclerosis: Geographic Distribution





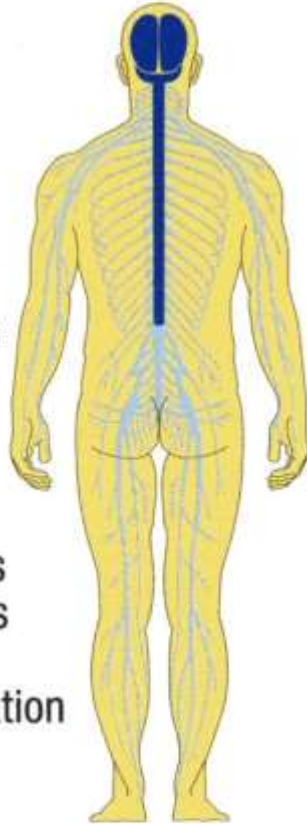
# Sunlight Exposure & MS infection

- ▶ Vitamin D is thought to be a key factor in the development of MS.
- ▶ By just analyzing sunlight, they could explain 61% of the variation in the number of MS cases across England.
- ▶ Latitude and risk for MS: HLA-DRB1\*1501 gene expression is partially regulated by vitamin D, thus explaining the long known connection between latitude and risk for MS

## Symptoms

MS is an autoimmune disease, leading to impaired function of the central nervous system; symptoms are scattered in time and space:

- visual impairment
- impaired speech
- fatigue
- cognitive disorders (forgetfulness)
- sensory disorders, tingling, abnormal sensations in limbs or trunk, numbness
- impaired co-ordination
- impairment of bladder emptying
- impaired mobility (muscle tension, stiffness), problems with walking; stumbling, weakness

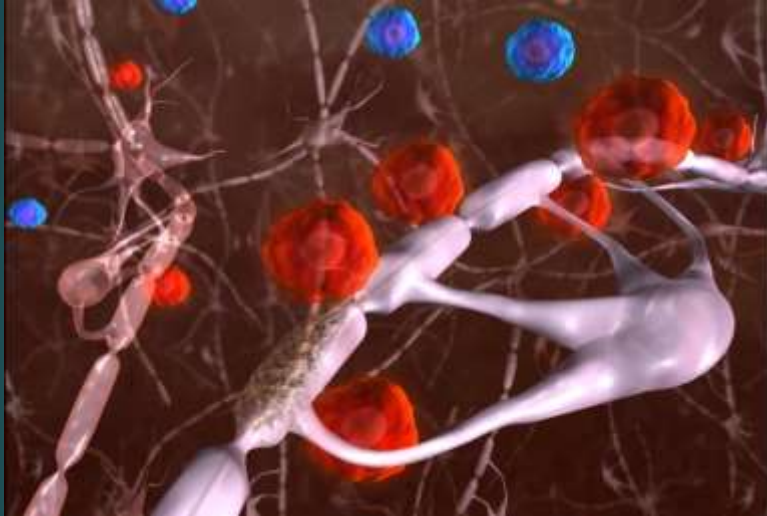


## Presenting features of MS

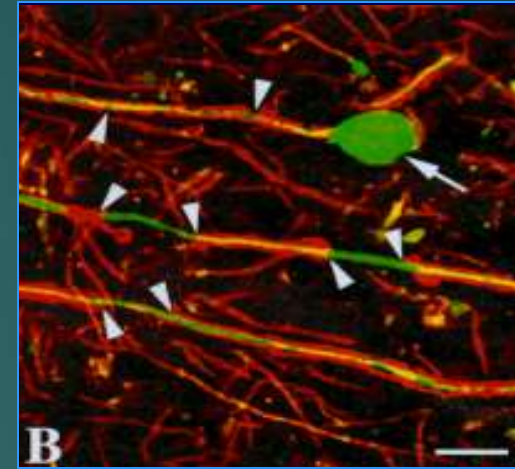
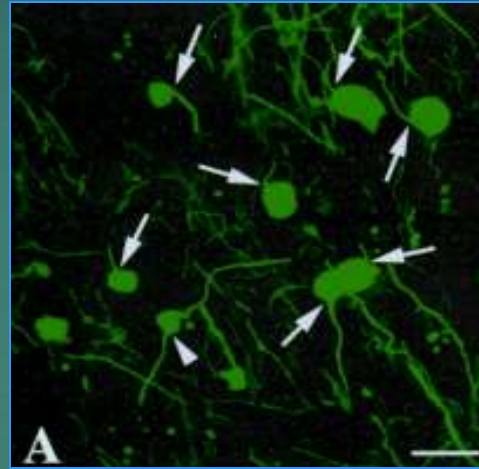
Limb weakness	50%
Optic neuritis	20%
Diplopia	10%
Parasthesia	10%
Bladder Parasthesia	10%
Vertigo and nystagmus	5%

# MS Characteristics

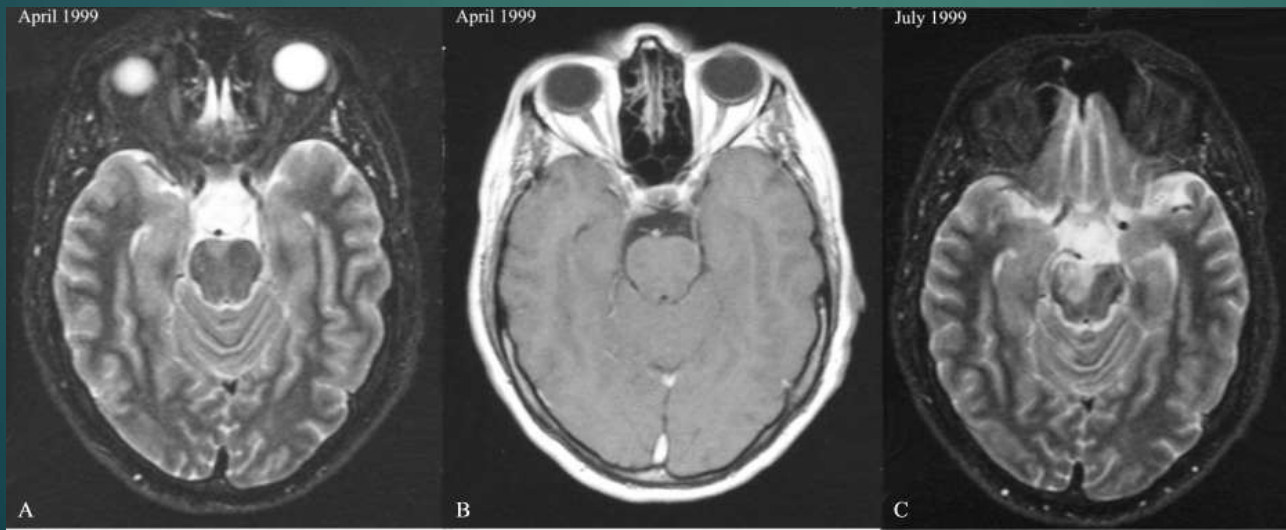
1. Immune-mediated CNS disease



2. Characterized by demyelination and axonal loss → neurologic impairment and disability



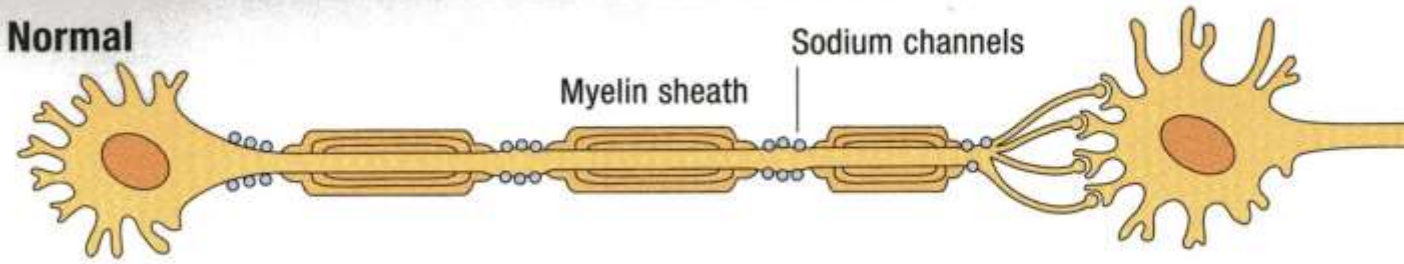
3. Dissemination of lesions in time & space



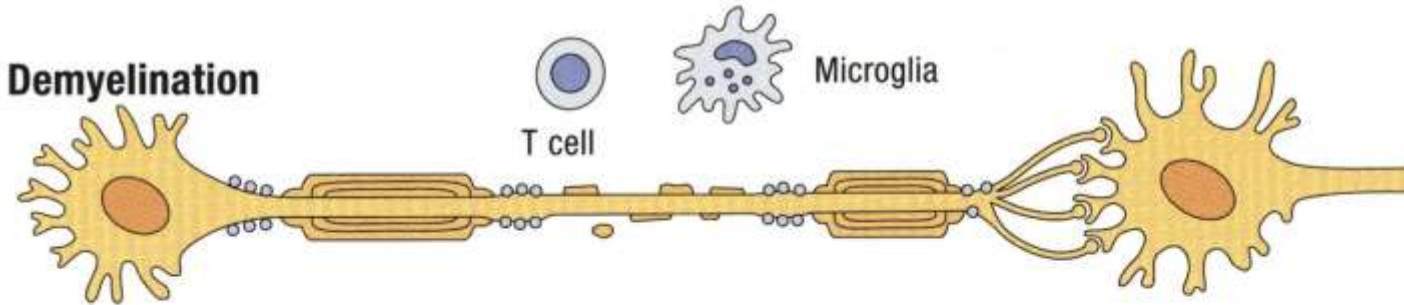


## Nerve fibre: damage to myelin sheath

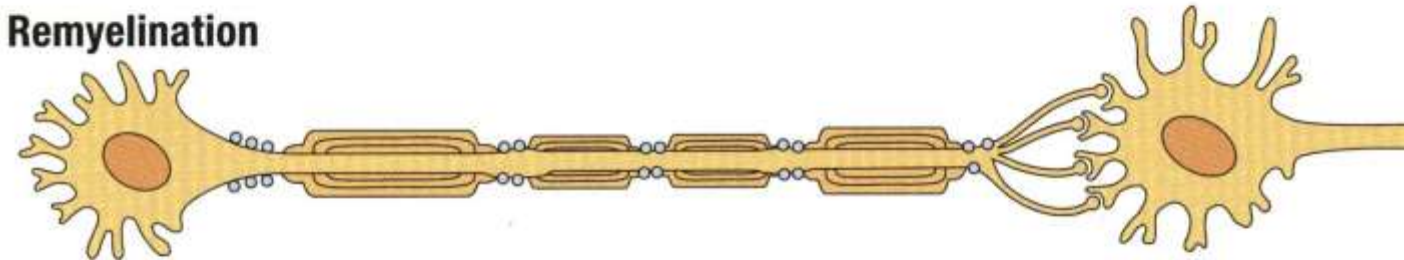
**Normal**



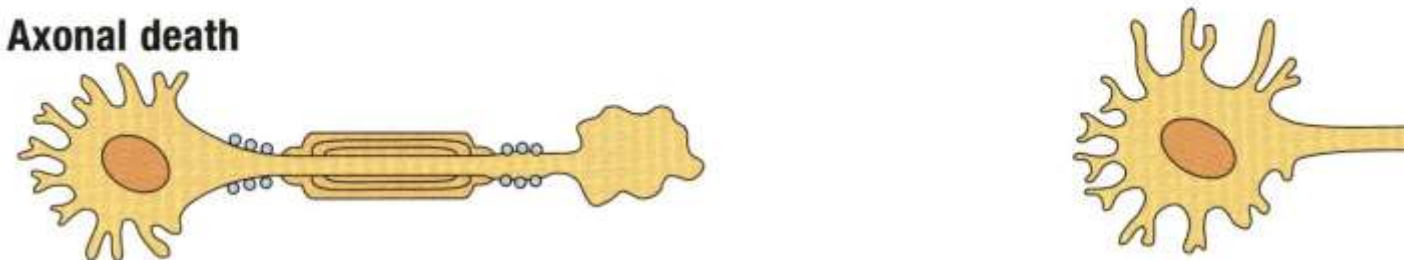
**Demyelination**



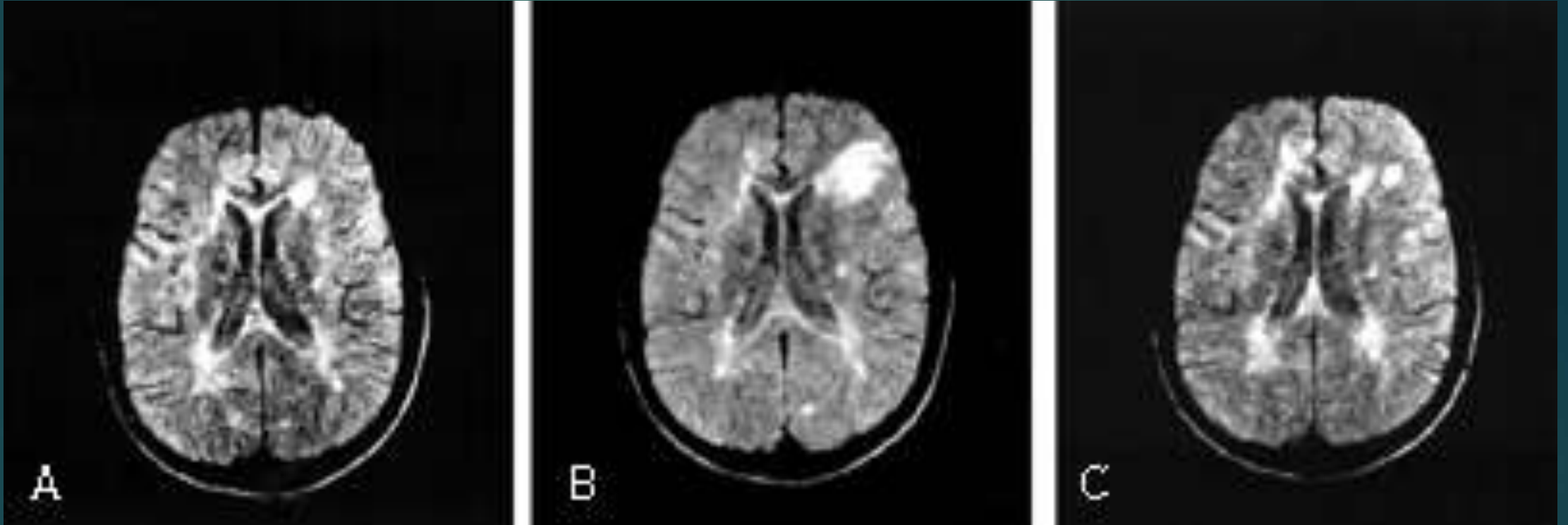
**Remyelination**



**Axonal death**

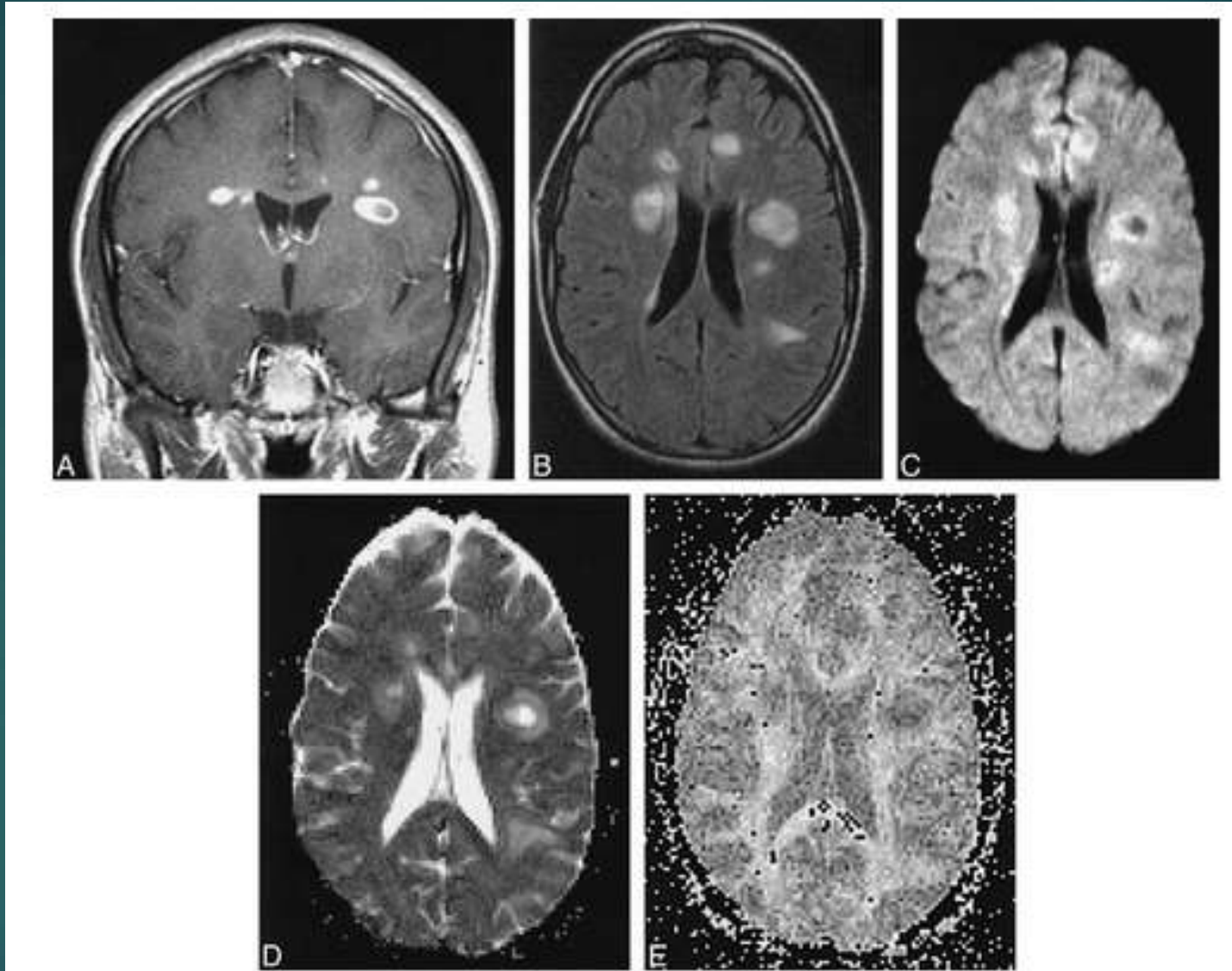


# MRI of Multiple Sclerosis

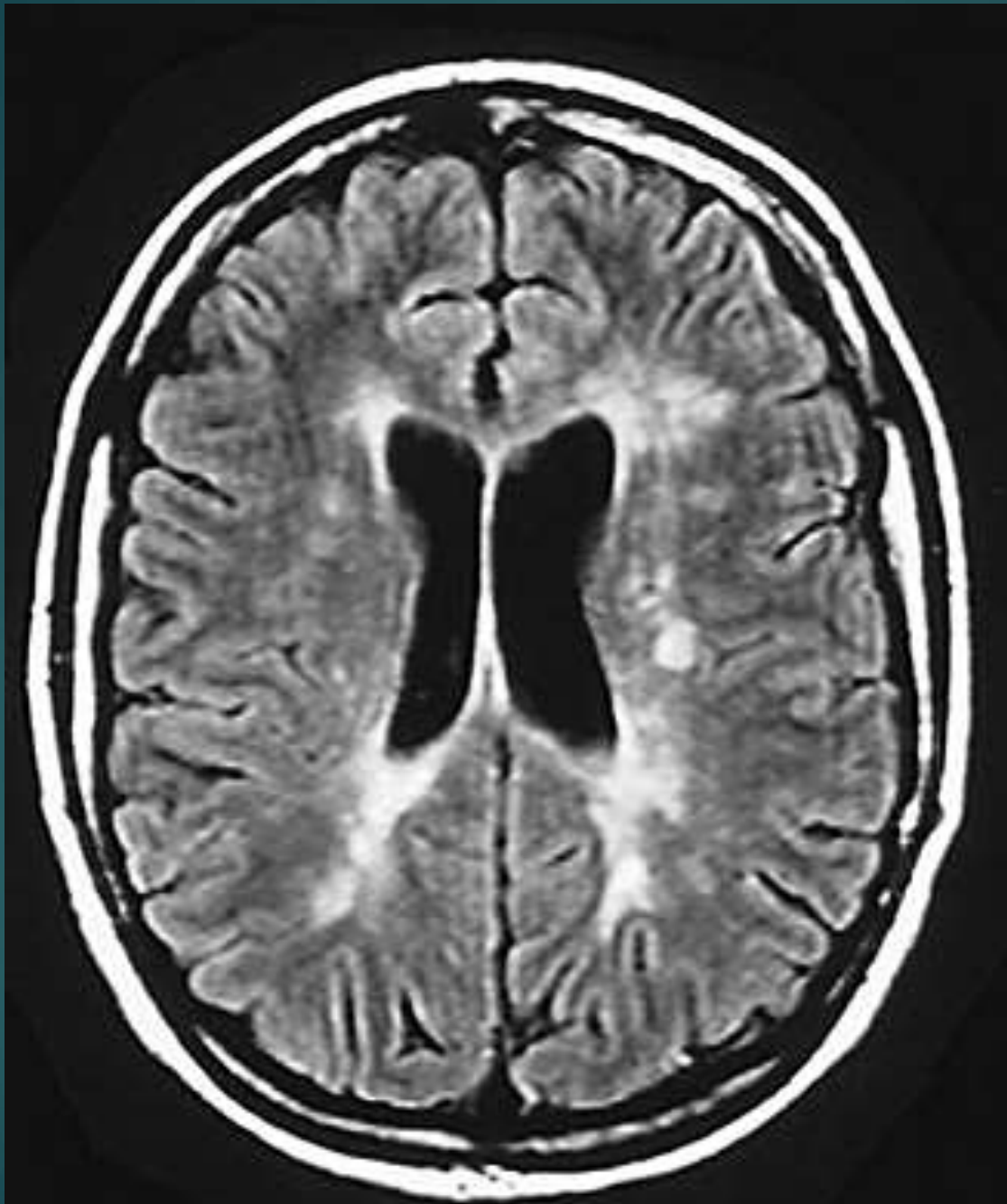




A: T1  
B: Flair  
CDE:  
DTI



22 yo woman with acute plaques and multiple neurologic signs and symptoms of 2 to 4 weeks' chronicity at first presentation of MS.



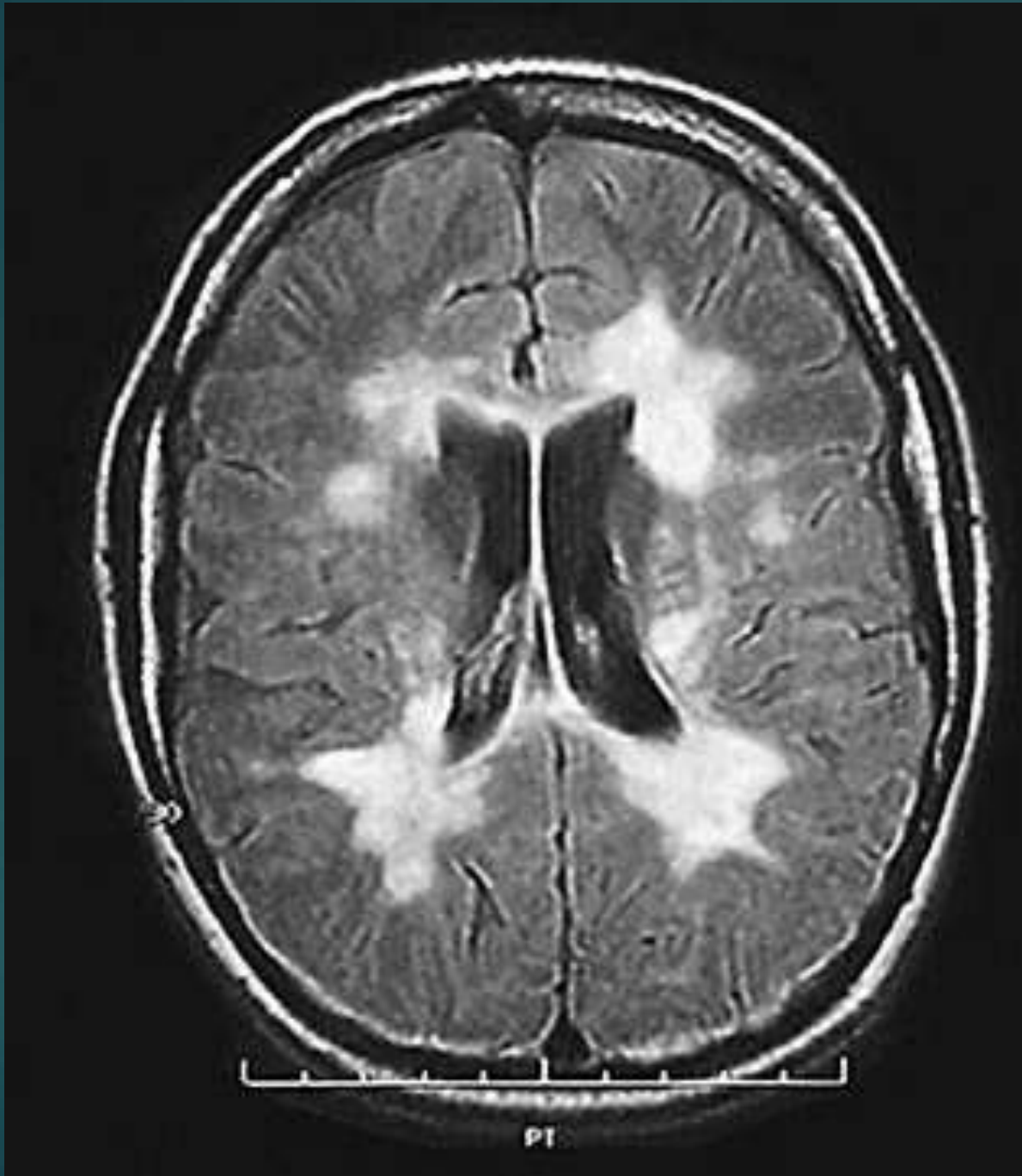
Hx: 25 yr woman  
with relapsing-  
remitting MS

Axial FLAIR

Periventricular  
hyperintense  
WM lesions

NEJM 343:938-52, 2000

9 months later

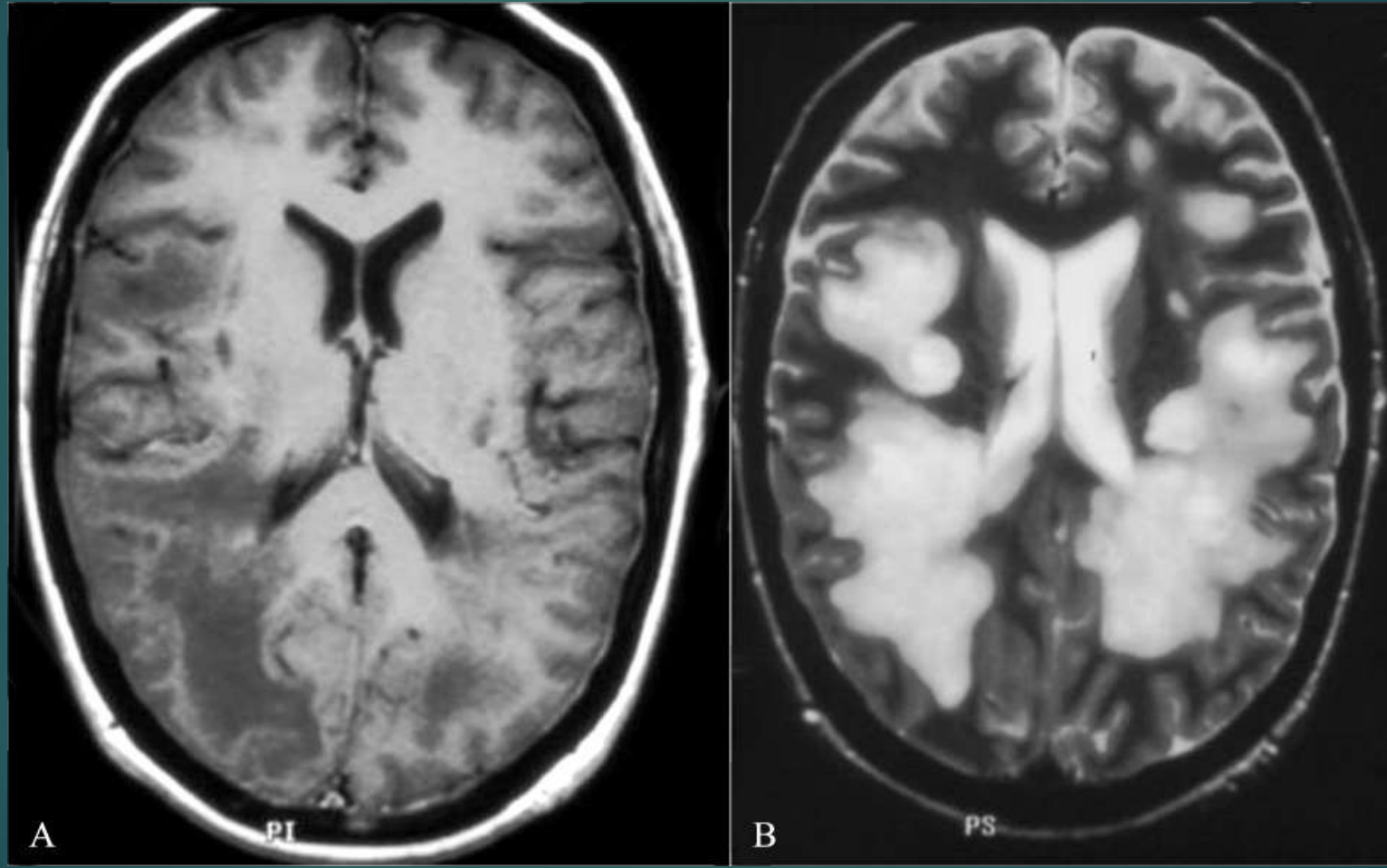


Axial FLAIR

↑ number &  
↑ size of  
WM lesions

NEJM 343:938-52, 2000

# Severe demyelination

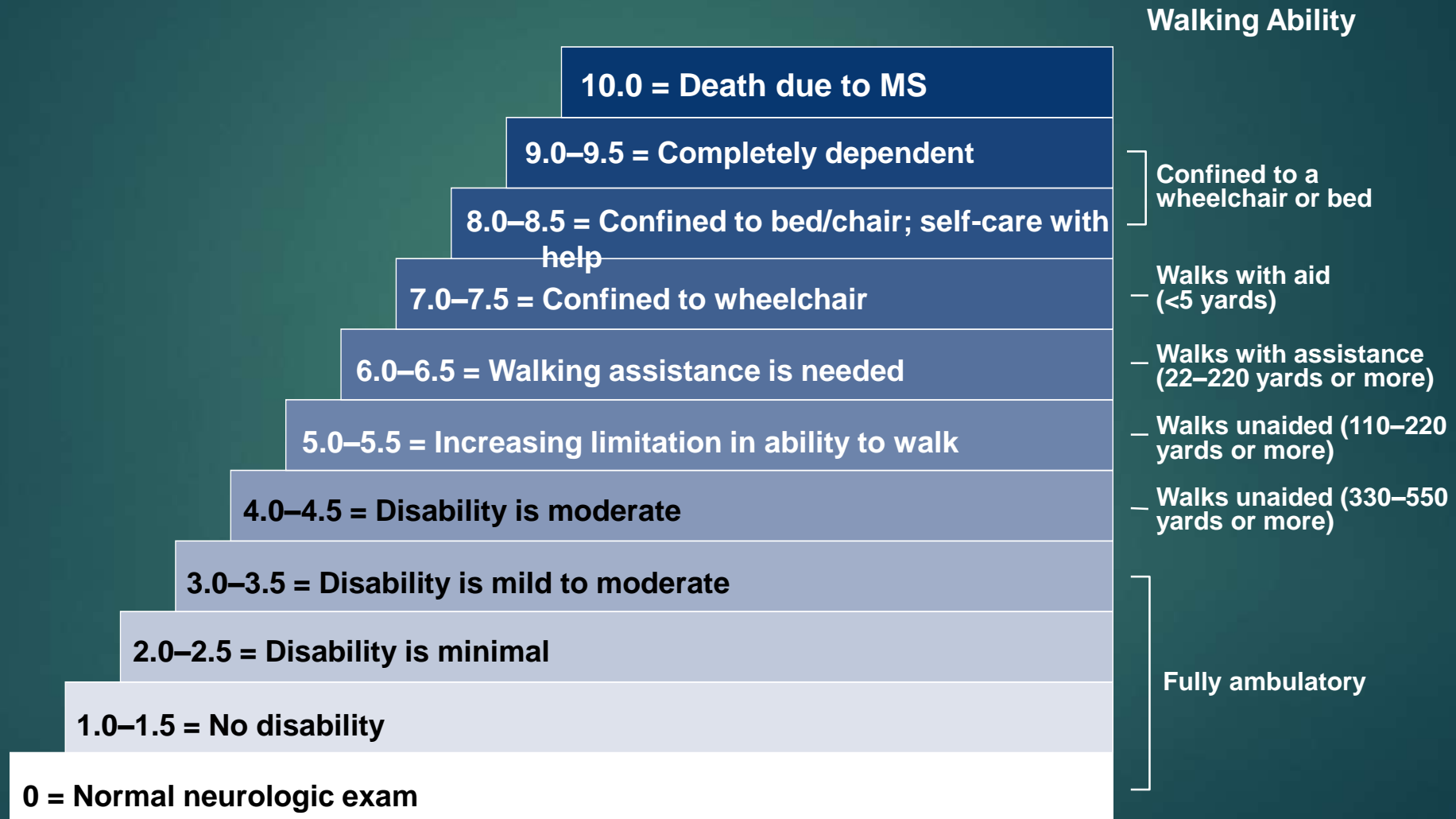

# Multiple Sclerosis

- ▶ **Cognitive impairments:**
  - ▶ divided attention (PASAT),
  - ▶ verbal retrieval memory,
  - ▶ visual memory (Rey: retrieval down),
  - ▶ processing speed (SDMT best predictor),
  - ▶ executive functioning (greater during disease activity): working memory, set shifting



# Kurtzke Expanded Disability Status Scale (EDSS): Progression to Disability



# Infections and Autoimmune Disorders:

## Cause white matter injury

- ▶ Systemic Lupus Erythematosus (SLE) (cerebritis, vasculitis (inflammation of blood vessels)); fluctuates with disease state:
  - ▶ Retrieval, visual WM, verbal fluency, processing speed, cognitive flexibility
  - ▶ white matter hyperintensities is its most common conventional MRI finding, and frequently affects cognition at an early stage
- ▶ Eosinophilia-myalgia Syndrome (EMS): (L-Tryptophan induced; sensory pain; causes ischemia, demyelination, infarcts):
  - ▶ Selective and divided attention, processing speed, visual free recall, executive functioning
- ▶ HIV: processing speed, attention, memory, executive functioning

# Toxic Leukoencephalopathy

- ▶ Variability: Diverse mechanisms; Target of injury (myelin, astrocytes, blood vessels, etc.)
- ▶ Etiologies:
  - ▶ Cranial irradiation
  - ▶ Therapeutic drugs (antineoplastics - anticancer)
  - ▶ Drugs of abuse (cocaine, heroin, ecstasy or MDMA, toluene, etc.)
  - ▶ Environmental solvents (organic solvents)

# Toxic Leukoencephalopathies

- Clinical outcome:
- WM tracts for higher cerebral function affected
- Inattention
- Forgetfulness
- IQ
- Changes in personality
- Dementia
- Coma
- Death
- Absence of aphasia, language preserved

# Ethanol Leukotoxicity

- ▶ Alcoholics have ↑ hyperintense WM foci
- ▶ Frontal WM preferentially affected
- ▶ Fetal alcohol syndrome - delayed myelination & agenesis of the corpus callosum
- ▶ Marchiafava - Bignami
- ▶ Atrophy of corpus callosum with necrosis



## Alcoholism: recovery brings back WM

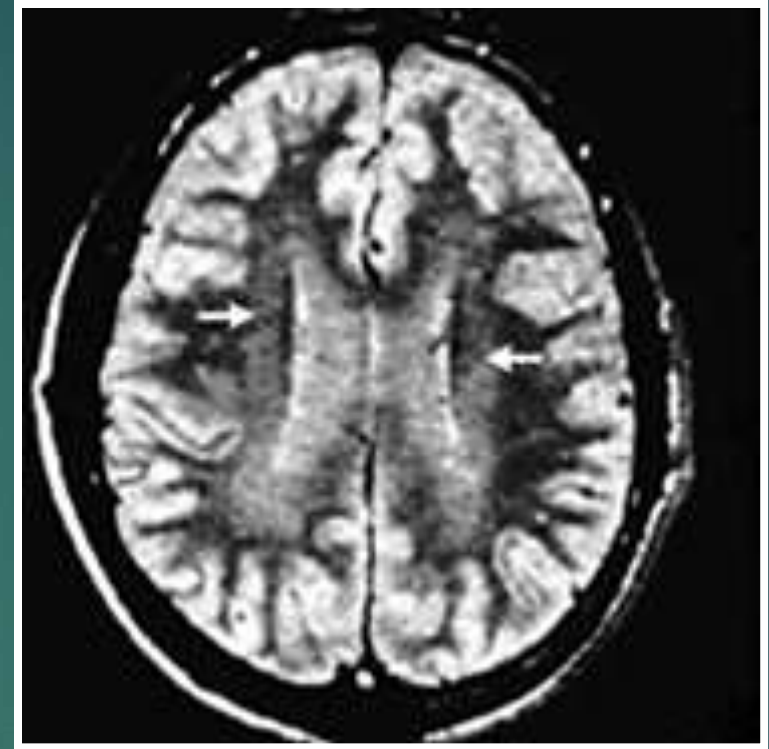
- ▶ Abstinence followed by reversal of sulcal and ventricular enlargement
- ▶ Increased cortical grey matter after 2-4 weeks of sobriety
- ▶ Increase in white matter volume related to decrease in 3rd ventricular size, 2-7 months

## Neurotoxic WM Injury (due to solvents)

- ▶ Demyelination and ischemic effects
- ▶ Cognitive: memory acquisition, processing speed
- ▶ Psychiatric Symptoms: depression, impaired behavioral control

## Solvents: Toluene – myelin degradation

- ▶ Spray paints, varnishes, thinners, dyes, glues, histology reagents, & aviation fuels
- ▶ Abused as an inhalant (glue-sniffing)



T2 MRI in man with dementia and long-term toluene abuse  
Symmetric hyperintensity of WM & ventricular enlargement

## Childhood cancer Tx

- ▶ There are neurocognitive late effects of treatments for childhood cancer such as difficulties with attention, processing speed and visual-motor ability and these are the result of white matter damage.
- ▶ White matter damage is responsible for the more subtle neurocognitive late effects resulting from treatment for childhood leukemia.
- ▶ Patients who have survived bone marrow transplant as treatment for childhood leukemia are at particular risk for neurocognitive late effects,

# Tests that measure white function

- ▶ Cranial radiation therapy has been strongly implicated in white matter changes;
- ▶ Chemotherapy alone is also thought to have similar effects;
- ▶ Evidence of small hemorrhages & swelling (& decreased white matter diffusion anisotropy) in the white matter have been found in a greater proportion of leukemia survivors, which has been attributed to neurotoxicity of methotrexate and to radiation.
- ▶ Correlates with IQ decrease.



# White Matter NP measures

- ▶ Attention, processing speed, and visual-spatial and visual-motor coordination are thought to reflect white matter functioning.
- ▶ **WM function measures:**
  - ▶ processing speed (Performance IQ (Block Design, Digit Symbol))
  - ▶ Judgment of Line Orientation,
  - ▶ sustained attention measures (CPT),
  - ▶ EF measures

# Radiation

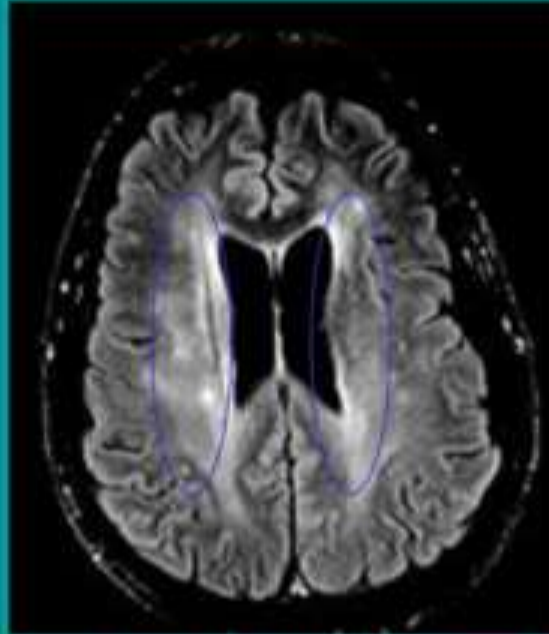
- ▶ More common for whole brain > local field
- ▶ 180-200 fractions per day x 6 weeks; Gamma knife is high dose, burns out area
- ▶ Neurobehavioral dysfunction in 28%
- ▶ Relation between dose and white matter change
- ▶ Acute: edema, elevated ICP

# Radiation 2

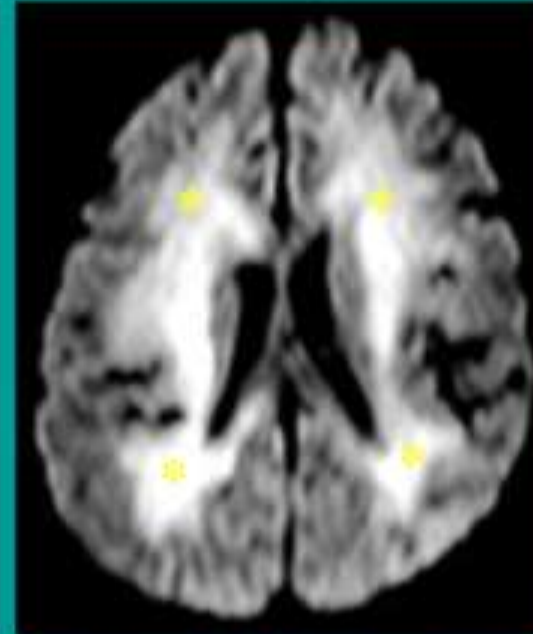
- ▶ **3 stages:**
  - ▶ acute reaction - patchy, reversible WM edema
  - ▶ delayed reaction - widespread edema & demyelination (inhibition of myelin synthesis)
  - ▶ severe delayed reaction - loss of myelin and axons due to vascular necrosis and thrombosis
- ▶ Cognitive: often delayed onset at 2-3 years; verbal LTM retrieval and WCST deficits; if younger than 7, IQ decrease

# Radiation & Chemotherapy

- Often symmetric bilaterally with scalloped outer margins
- Frequently involves periventricular WM
- Associated w/ atrophy
- Often shows variable peripheral enhancement & **restricted diffusion**
- PET or perfusion MRI may be helpful to distinguish from tumor



Axial FLAIR MRI *McKinney, et al*



Axial DWI MRI *McKinney, et al*

# Chemotherapy

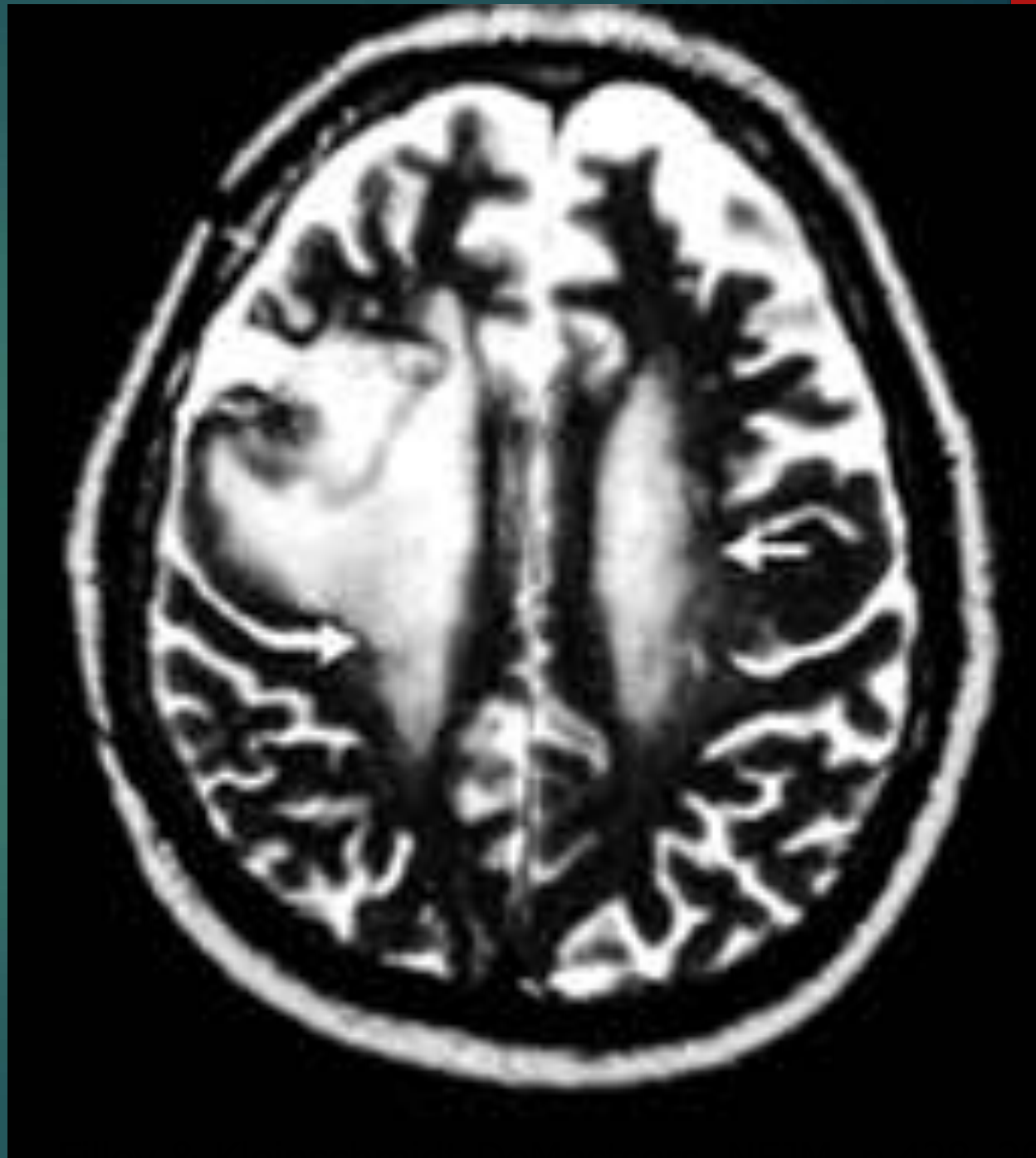- ▶ Many of the cancer chemotherapeutic drugs are neurotoxic.
- ▶ Acute: High-dose intravenous methotrexate is the most common cause.
- ▶ The bilateral diffuse white matter hyperintensity is transient in nature, and patients may be entirely asymptomatic.
- ▶ Chemo brain: current idea is inflammatory effects of both cancer & chemo



# Chemotherapy drugs

- ▶ Especially those given intrathecally (spinal cord)
- ▶ Especially when given with irradiation
- ▶ Methotrexate - discrete or confluent necrosis - can cause MNL, - vascular lesions in some
- ▶ Carmustine
- ▶ Others (cisplatin, cytarabine, fluorouracil, levamisole, fludarabine, thiopeta)
- ▶ Sometimes IL-2, interferon-alpha

T2-MRI in man with  
right frontal GBM  
after radiation &  
chemotherapy  
with carmustine  
Shows symmetric  
hyperintensity  
of the cerebral  
white matter  
(2 arrows)



## Chemotherapy 2

- ▶ Delayed: The delayed effects of chemotherapy range from asymptomatic white matter hyperintensities to a severe necrotizing leukoencephalopathy (MNL).
- ▶ The onset of clinical and imaging findings is earlier than that observed with radiation, usually a few weeks or months following therapy.
- ▶ The reported incidence of necrotizing leukoencephalopathy varies widely, but is much higher with CNS leukemia, or when combinations of intravenous and intrathecal chemotherapy and radiation is employed

# Paranoid Psychosis

(Paranoid Schizophrenia and Late Onset Paranoid Psychosis)

- ▶ Paranoid Schizophrenics:
  - ▶ 23% had WM hyperintensities  
14% had moderate-severe
  - ▶ 49% showed ventricular enlargements
  - ▶ 43% showed cortical atrophy

# Paranoid Psychosis 2

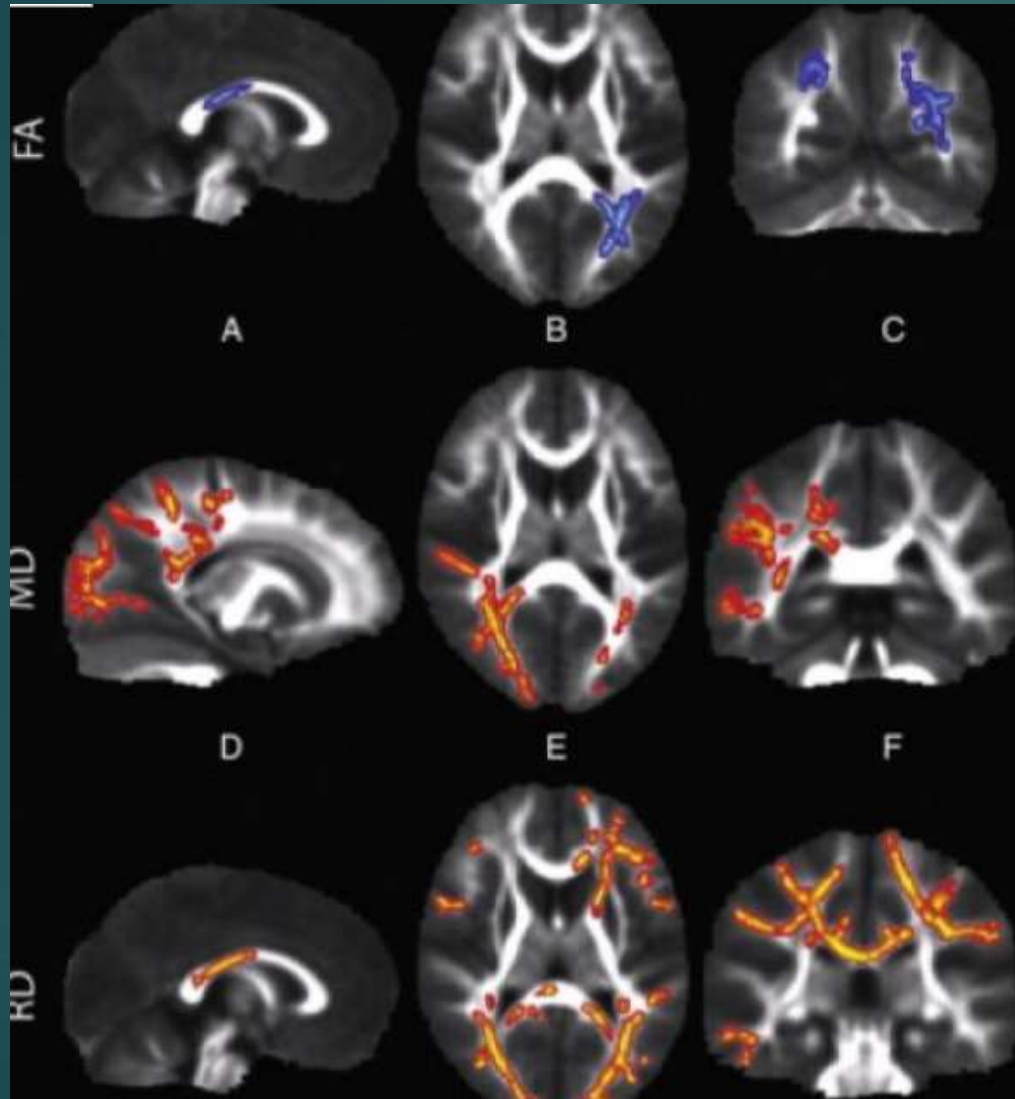
- ▶ Late Onset Paranoid Psychosis:
  - ▶ 69% had white matter hyperintensities  
54% mod-severe
  - ▶ 38% showed mild ventricular enlargement
  - ▶ 31% showed mild cortical atrophy

# Sensory Processing Disorder (SPD)

- ▶ SPD more prevalent in children than autism; often occurs in children who also have ADHD or autism
- ▶ Sensory processing disorders affect 5 to 16 % of school-aged children.
- ▶ Children with SPD struggle with how to process stimulation, which can cause a wide range of symptoms including hypersensitivity to sound, sight and touch, poor fine motor skills and easy distractibility. Difficulty with emotional regulation and distraction. In the real world, they're just less able to process information efficiently.



# SPD: abnormal white matter tracts; higher FA



*Row FA: The blue areas show white matter where water diffusion was less directional than in typical children, indicating impaired white matter microstructure.*

*Row MD: The red areas show white matter where the overall rate of water diffusion was higher than in typical children, also indicating abnormal white matter.*

*Row RD: The red areas show white matter where SPD children have higher rates of water diffusion perpendicular to the axonal fibers, indicating a loss of integrity of the fiber bundles comprising the white matter tracts. (Credit: Image courtesy of UCSF)*

# Autism

- ▶ Increased brain volume in autism appears to be driven mainly by an unexplained white matter enlargement (there is a similar phenomenon in developmental language disorder (DLD))
- ▶ Studies of the volume of white matter have suggested an early overgrowth of white matter among young children with autism, followed by reduced white matter in adolescence and adulthood relative to controls
- ▶ Findings of reduced functional connectivity

# Sleep Apnea

- ▶ Bilateral white matter involvement has been seen in pts. with moderate to severe OSA (as well as grey matter decrease)
- ▶ The use of continuous positive airway pressure (CPAP) correlates with improvement in white matter deficits seen in patients with obstructive sleep apnea (OSA).
- ▶ These changes correlate with improvements in neurocognitive functioning. The changes may take up to a year to become evident on white matter imaging.

# Aerobic Exercise and DNW & Frontal Executive Network

- ▶ DMN connectivity was significantly improved in the brains of the older walkers, but not in the stretching and toning group, the researchers report.
- ▶ The walkers also had increased connectivity in parts of the fronto-executive network and they did significantly better on cognitive tests than their toning and stretching peers.

# Less UBOs with Mediterranean Diet

- ▶ Med. diet protects against blood-vessel damage in the brain, reducing the risks of stroke and memory loss.
- ▶ Previous studies have suggested adhering to a Mediterranean-style diet is associated with a lower risk of heart disease, stroke and cognitive disorders like Alzheimer's disease.
- ▶ Broadly, the study showed that people with the highest Mediterranean diet scores had the lowest white-matter volume burden.
- ▶ Those who consumed more monounsaturated fat, which is found in olive oil, had lower white-matter hyperintensity volumes on their brain scans.

## Inherited metabolic disorders: rare, progressive, metabolic, genetic diseases

- ▶ Inherited metabolic disorders affecting the brain are complex, heterogeneous and have varied clinical symptoms, but primarily present with **progressive functional deterioration** without treatment
- ▶ Cross-sectional imaging can be helpful, especially MRI, which can be tailored to narrow the differential diagnosis and guide further evaluation and treatment. **Bilateral symmetric findings are typical.**
- ▶ Characteristic imaging findings and patterns suggesting metabolic brain disease should prompt further genetic/ metabolic evaluation, particularly when the clinical history is nonspecific.



# Summary: Predominantly White Matter

	Causes	Classic Radiographic findings	Remarks
<b>Pelizaeus - Merzbacher disease</b>	Hypomyelination	<p><b>Location:</b> Isolated WM involvement</p> <p><b>Description:</b> Hypomyelination compared to patient's age</p>	<ul style="list-style-type: none"> <li>• Prototype of hypomyelination</li> <li>• Lack of normal myelin maturation</li> </ul>
<b>Metachromatic Leukodystrophy</b>	Lysosomal storage disorder	<p><b>Location:</b> Anterior and posterior deep white matter</p> <p><b>Description:</b> Confluent butterfly-shaped T2 hyperintensity involving deep cerebral white matter</p>	<ul style="list-style-type: none"> <li>• Anterior and posterior</li> <li>• Central WM</li> <li>• Sparing subcortical U fiber in early course</li> <li>• No enhancement</li> <li>• Tigroid appearance</li> </ul>
<b>X-linked adrenoleukodystrophy</b>	Peroxisomal disorder	<p><b>Location:</b> Posterior/peritrigonal white matter</p> <p><b>Description:</b> Confluent T2hyperintensity involving predominantly parietooccipital white matter (posterior) and splenium of corpus callosum</p>	<ul style="list-style-type: none"> <li>• Posterior location</li> <li>• Central WM</li> <li>• Restricted diffusion and enhancement in the edge of the lesions</li> <li>• Can be frontal (anterior) in atypical cases (10%)</li> </ul>
<b>Alexander disease</b>	Other Leukodystrophy (Mutation of glia fibrillary acidic protein (GFAP))	<p><b>Location:</b> Anterior periventricular &gt; subcortical white matter ± BG, thalami, brain stem, cerebellum, fornix, optic chiasm, spinal cord</p> <p><b>Description:</b> Confluent T2hyperintensity involving predominantly frontal white matter (anterior)</p>	<ul style="list-style-type: none"> <li>• Anterior predominantly</li> <li>• Central WM</li> <li>• Enhancement in the edge of the lesions</li> <li>• Macrocephaly</li> </ul>

# Summary: Predominantly Gray matter

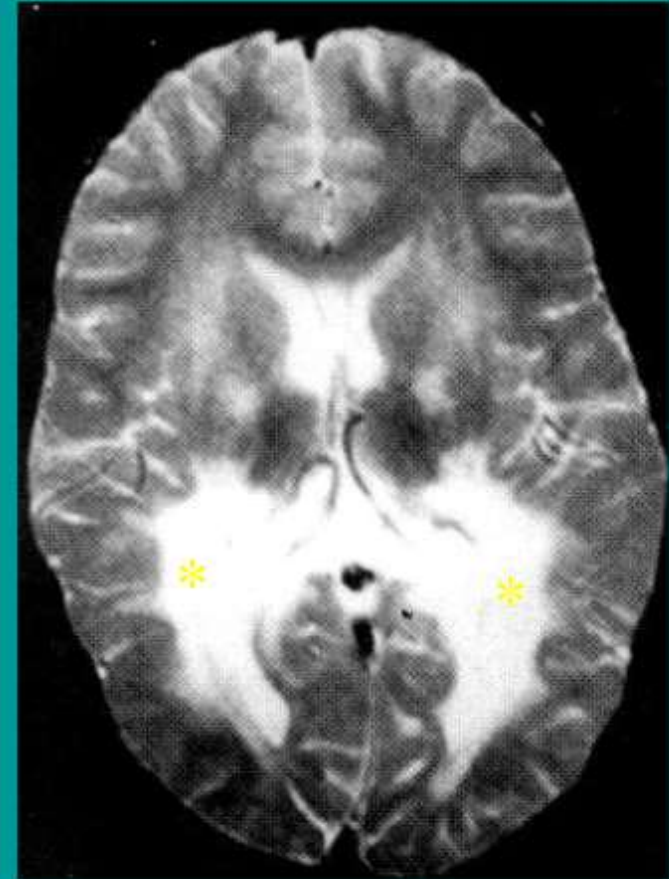	Causes	Classic Radiographic findings	Remarks
<b>Leigh syndrome - Non- <i>SURF1</i> mutation</b>	Mitochondrial disease	<b>Location:</b> BG: putamen > caudate heads > globi pallidi BS: periaqueductal gray matter, substantia nigra/subthalamic nuclei Thalami and dentate nuclei  <b>Description:</b> Symmetrical areas of T2/FLAIR hyperintensity with restricted diffusion in acute phase	<ul style="list-style-type: none"><li>• Restricted diffusion in acute phase</li><li>• No contrast enhancement</li></ul>
<b>Leigh syndrome - <i>SURF1</i> mutation</b>	Mitochondrial disease	<b>Location:</b> Lower BS (pons, medulla) with <b>mild BG involvement</b>  <b>Description:</b> Symmetrical areas of T2/FLAIR hyperintensity with restricted diffusion in acute phase	<ul style="list-style-type: none"><li>• Lower BS (pons, medulla) with mild BG involvement</li></ul>
<b>MELAS</b>	Mitochondrial disorder	<b>Location:</b> Posterior cerebral hemisphere and basal ganglia  <b>Description:</b> Stroke-like lesions, varying age. Do not follow vascular territory.	<ul style="list-style-type: none"><li>• <b>Consider MELAS for unexplained strokes in pediatric patients</b></li></ul>

# Summary: Both Gray and White matter

	Causes	Classic Radiographic findings	Remarks
<b>Canavan disease</b>	Other Leukodystrophy: Autosomal recessive (Deficiency of enzyme aspartoacylase)	<b>Location:</b> Peripheral WM: <b>subcortical U-fiber</b> Deep Gray matter: Globi pallidi, thalami  <b>Description:</b> Confluent T2 hyperintensity involving subcortical U-fiber, globi pallidi, thalami with early sparing of the internal capsule and corpus callosum	<ul style="list-style-type: none"> <li>• <b>↑ NAA</b></li> <li>• No enhancement</li> <li>• Restricted diffusion in acute phase</li> </ul>
<b>Tay-Sachs disease</b>	Lysosomal storage disorder	<b>Location:</b> <b>Thalami</b> , striatum, cerebral >> cerebellar WM  <b>Description:</b> - Areas of T1 hyper/T2 hypointensity involving thalami - Hyperdensity on CT - Deep white matter delayed myelination	<ul style="list-style-type: none"> <li>• No contrast enhancement</li> <li>• No corpus callosum involvement</li> </ul>
<b>Krabbe disease</b>	Lysosomal storage disorder	<b>Location:</b> Central WM, corticospinal tract basal ganglia, and thalami  <b>Description:</b> Symmetrical confluent areas of T2/FLAIR hyperintensity involving central WM, cortical spinal tract, BG and thalami Cranial nerve and peripheral nerve enlargement and enhancement	<ul style="list-style-type: none"> <li>• Cranial nerve and peripheral nerve enlargement and enhancement</li> </ul>

# ALD: Adrenoleukodystrophy

- Leukodystrophies are metabolic & often present in infancy
- **ALD**
  - **Posterior distribution** involving periaxial & occipital WM, corpus callosum & fornix
  - May show enhancement
- Metachromatic Leukodystrophy
  - Frequently diffuse
- Alexander's Disease
  - Often has a frontal distribution

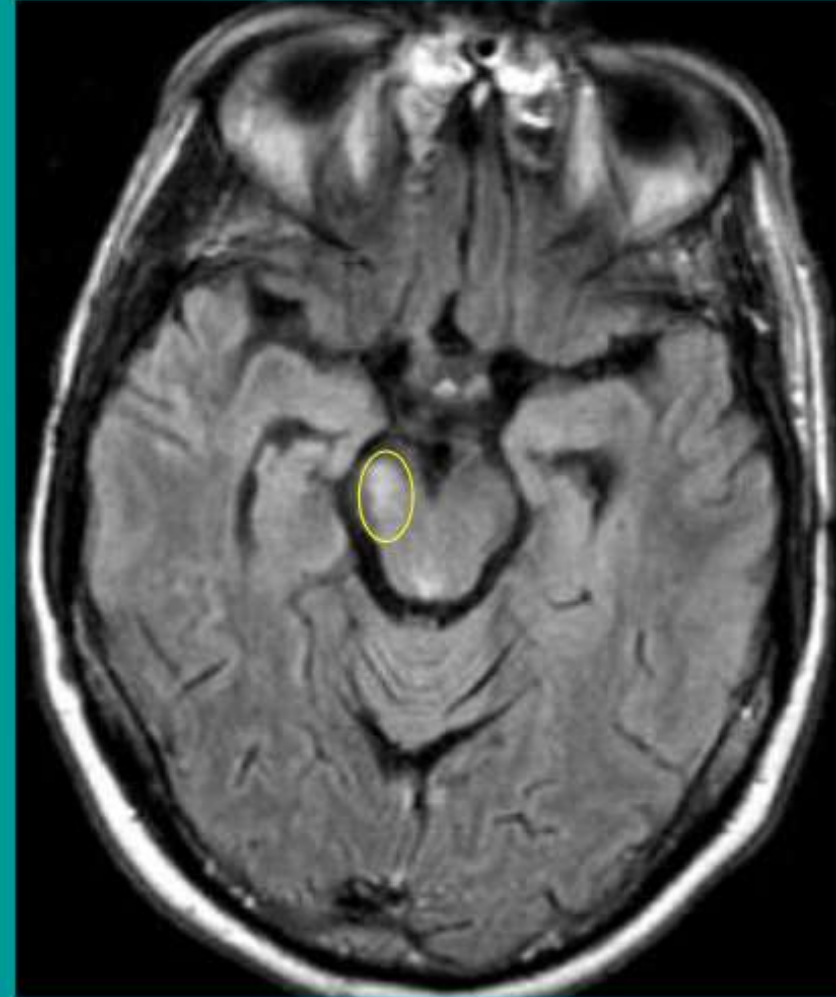


Axial T2 MRI *Courtesy of Dr. Rojas*



# Wallerian Degeneration

- Also known as orthograde or anterograde degeneration
- Involves injury to axons anywhere along their course
- In central nervous system (CNS), often involves **corticospinal tracts of cerebral peduncles**
- Myelin clearance by microglia in CNS is relatively slow compared to clearance by macrophages in peripheral nervous system.



Axial FLAIR MRI

*BIDMC PACS*

# Acquired Metabolic Demyelination

Central pontine myelinolysis (CPM)

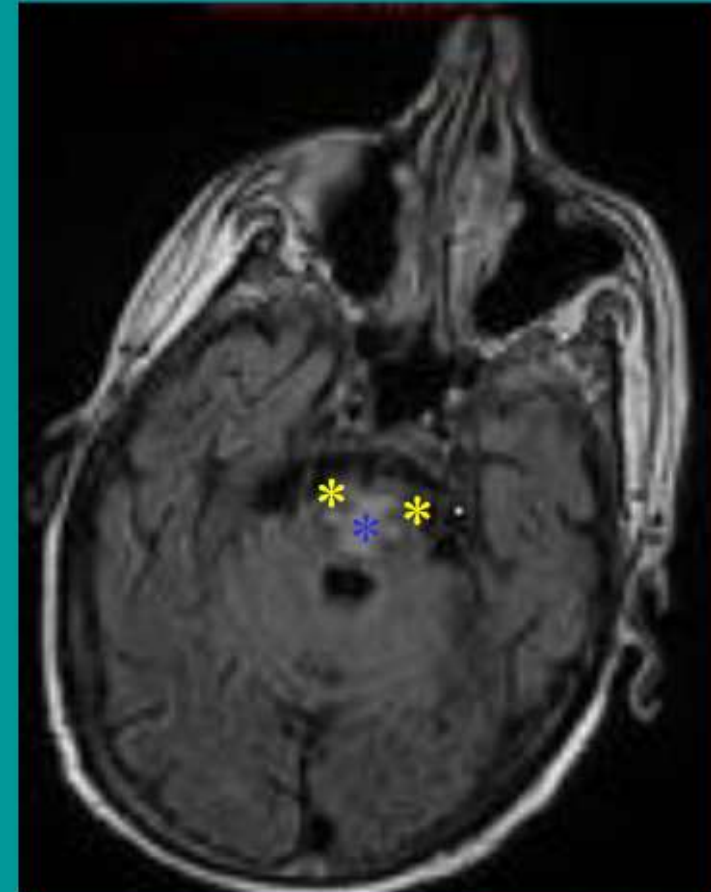
Multifocal necrotizing leukoencephalopathy (MNL)

Marchiafava-Bignami disease



# Central Pontine Myelinolysis

- Also known as osmotic demyelination syndrome
- Associated with
  - Rapid or overcorrection of hyponatremia
  - Alcoholism, malnutrition, debilitating disease
- Early
  - Localized to the **central pons**
  - Sparing of **corticospinal tracts**
    - “Snake eyes” appearance
- Extra-pontine myelinolysis
  - Commonly involves midbrain & basal ganglia.

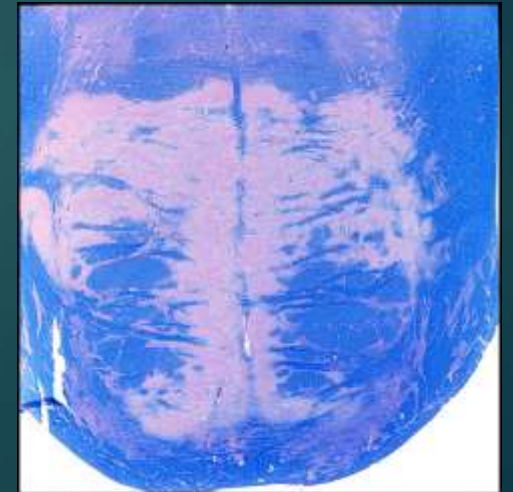


Axial T2 MRI

BIDMC PACS

# Central Pontine Myelinolysis

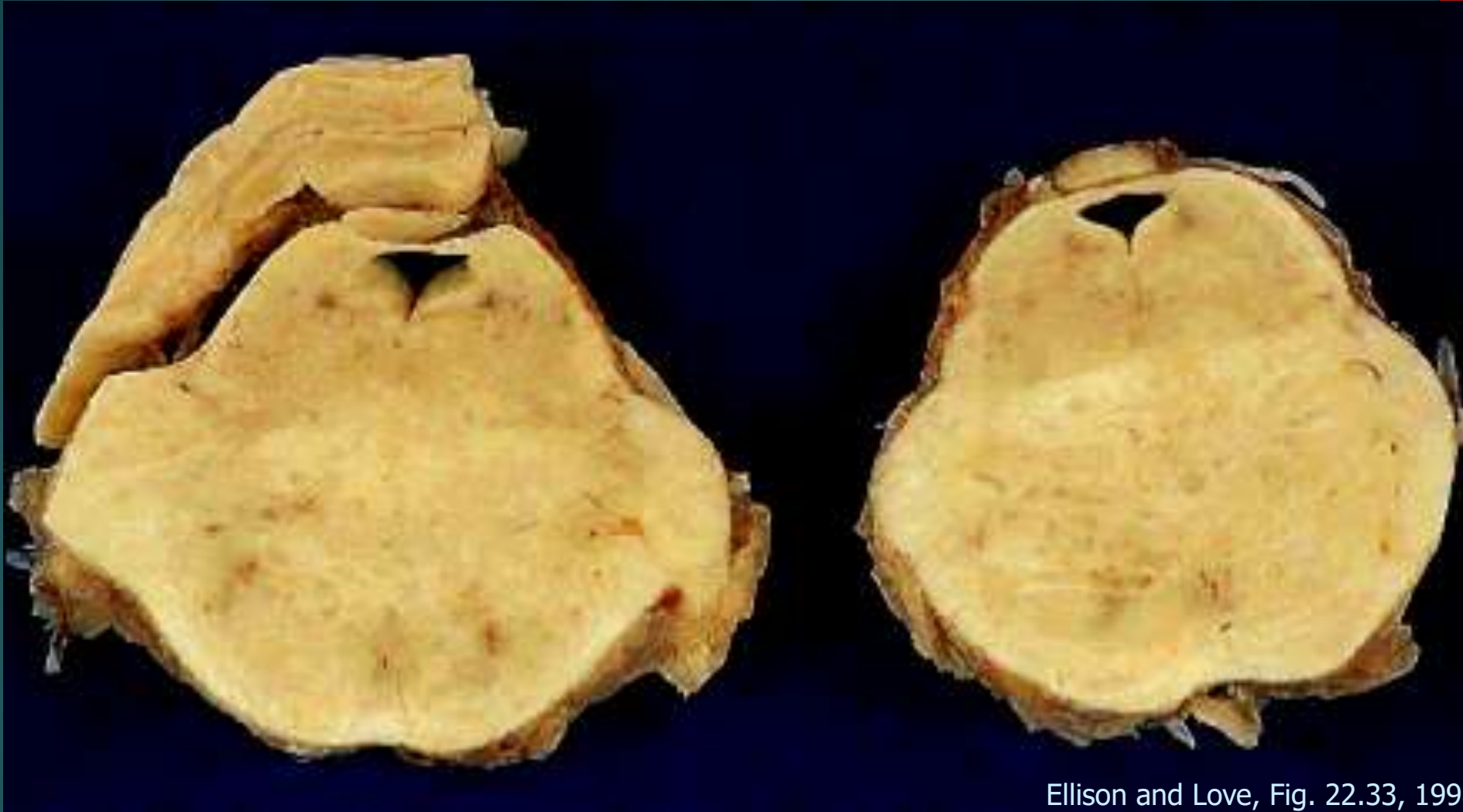- ▶ Rapid  $\uparrow$  serum  $\text{Na}^+$  in hyponatremic patient; Very similar to MS plaque
- ▶ Middle aged or elderly patients who are malnourished or chronically debilitated (chronic liver dz, alcoholics)
- ▶ Associated with fluid-electrolyte imbalance particularly where hyponatremia has been treated rapidly with hypo-osmolar saline
- ▶ Mechanism of demyelination is unknown but may relate to impaired vascular perfusion during the episode of rapid electrolyte shift
- ▶ Myelin loss usually occurs in the central pons



# Multifocal Necrotizing Leukoencephalopathy (MNL)

- ▶ Foci of necrosis with  $\text{Ca}^{++}$ , WM > GM
- ▶ Predominantly immunosuppressed patients (AIDS, leukemia, irradiation, amphotericin B, methotrexate, other cytotoxic drugs)
- ▶ Clinically - complex neurologic abnormalities in patients with long critical illnesses

# Multifocal Necrotizing Leukoencephalopathy



Ellison and Love, Fig. 22.33, 1998

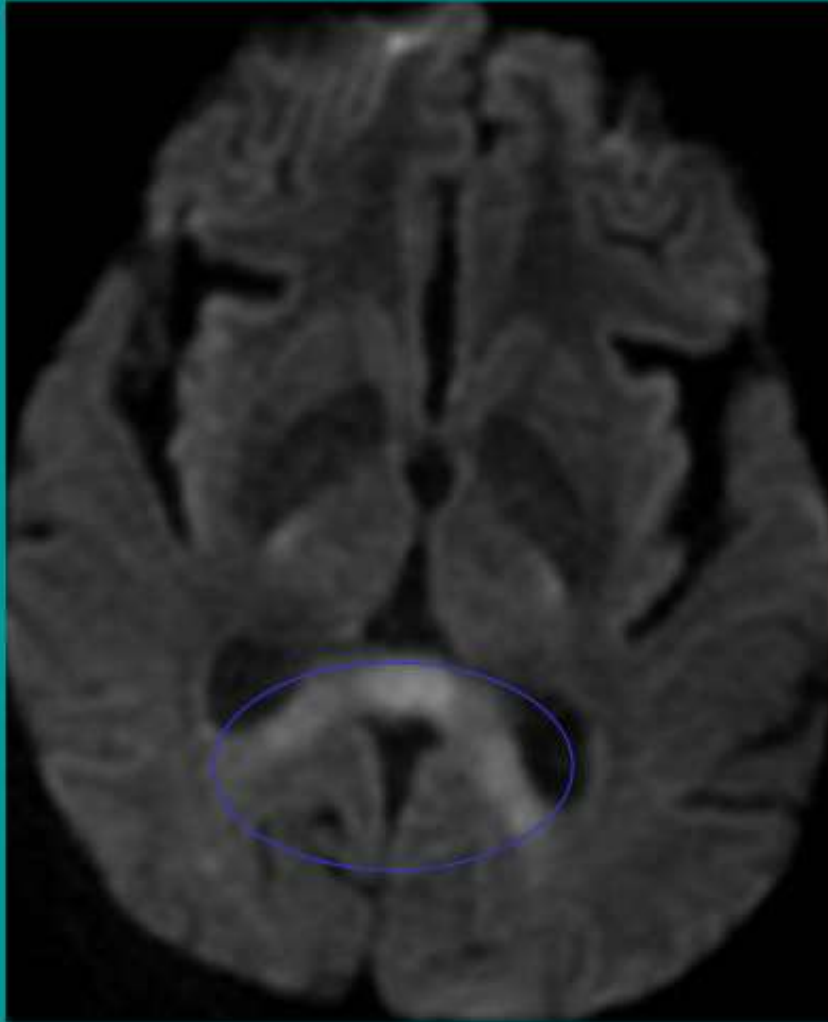
- ill-defined chalky white foci
- distributed in pons and white matter

# Marchiafava - Bignami Disease

- ▶ Rare complication of alcoholism
- ▶ Destruction of myelinated fibers; degeneration of corpus callosum & anterior commissure
- ▶ Loss of callosal fibers → cortical laminar sclerosis



- Relatively rare syndrome leading to demyelination & atrophy
- Characteristically involves corpus callosum
- More common in men
- Commonly associated with alcoholism
- Often shows restricted diffusion

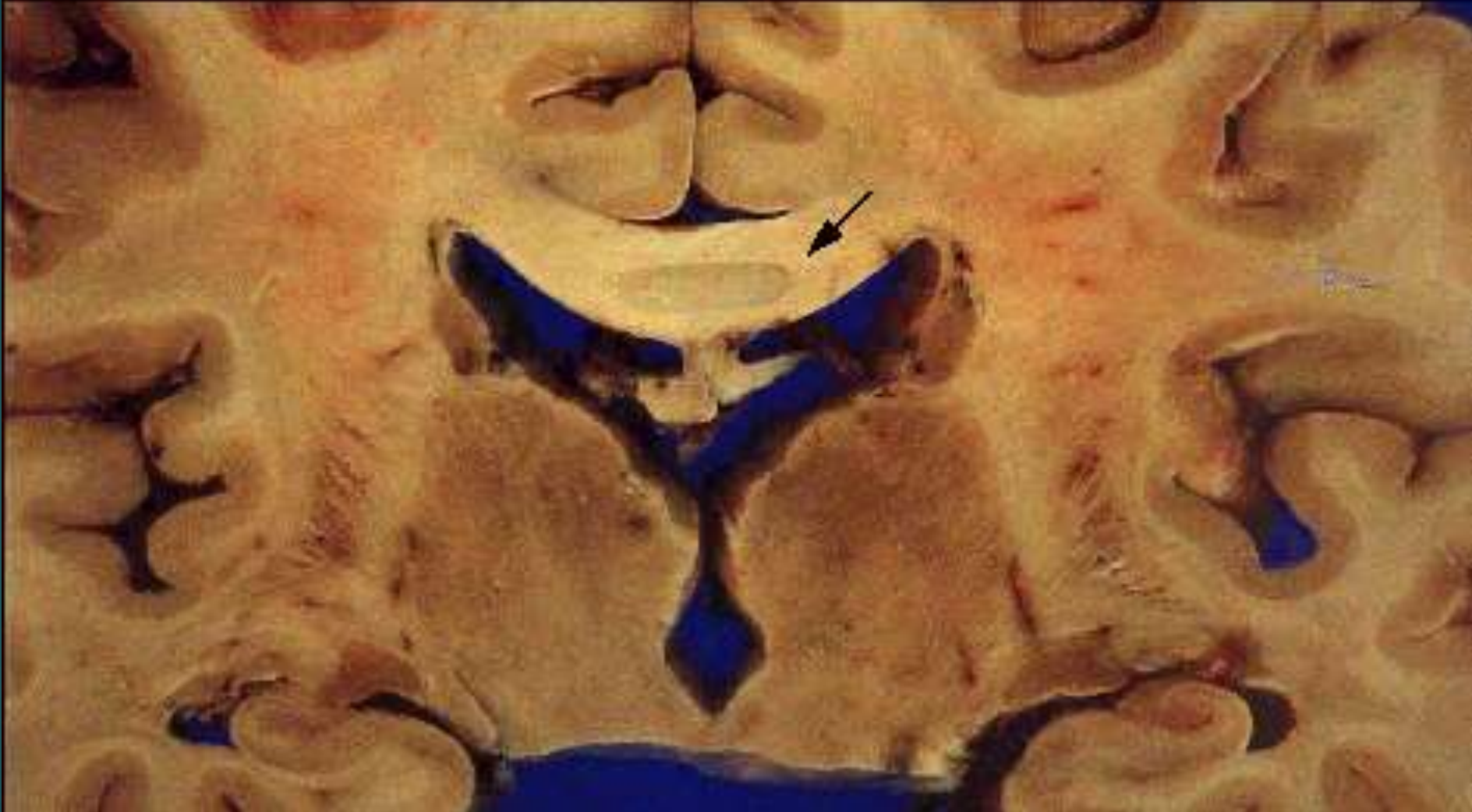


Axial DWI MRI

*Courtesy of Dan Ginat, M.D.*



# Marchiafava - Bignami Disease



Ellison & Love

# Guillain-Barré Syndrome

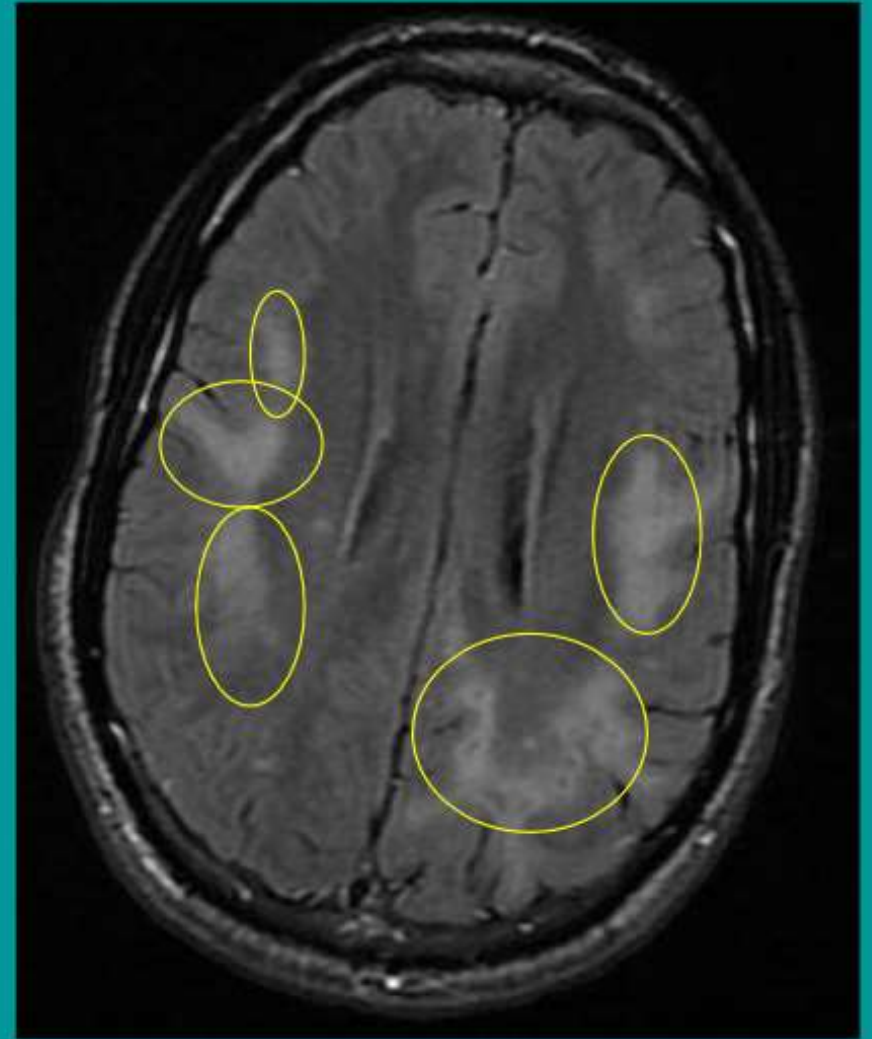
- ▶ Aka AIDP, acute inflammatory demyelinating polyneuropathy
- ▶ History: febrile illness 2-4 weeks prior to onset pain, paresthesias and ascending weakness
- ▶ Pathophysiology
  - ▶ grouping of acute immune mediated polyneuropathies; damages myelin and/or the myelin-producing Schwann cells of peripheral nervous system; can affect cranial nerves (facial paralysis)
- ▶ Recovery over weeks-couple months; initial severity doesn't correlate with length of course; 90% full recovery

# Progressive Multifocal Leukoencephalopathy (PML)

- ▶ Polyomavirus JC (often called JC virus) is carried by a majority of people and is harmless except among those with lowered immune defenses.
- ▶ Rare and fatal; progressive diffuse inflammation of WM
- ▶ Usually seen in middle age person with disorders affecting the immune system, such as: AIDS, malignancy, TB, and sarcoidosis.

# PML

- Involves reactivation of the John Cunningham (JC) virus in immunocompromised patients
- Male predominance
- Often involves
  - subcortical WM
  - corpus callosum
  - GM in up to 50%
- Enhancement is rare
- As with other multifocal processes, regions may become confluent over time.



Axial FLAIR MRI

*BIDMC PACS*

[www.charlesjvellaphd.com](http://www.charlesjvellaphd.com)

- ▶ All of my lectures in PDF files
- ▶ In Neuropsych Seminar section
- ▶ Logon: Kaiser
- ▶ Password: Kaiser
- ▶ Email: [charlesvella@comcast.net](mailto:charlesvella@comcast.net)



# Acute disseminated encephalomyelitis (ADEM)

## Number & age:

6 cases out of 40, age range were 6-55years, 4 were adult & 2 were children.

## Symptoms:

All having a history of fever prior to the onset of clinical symptoms, symptoms were altered consciousness (50%) followed by motor symptoms and urinary retention (33.3% each).

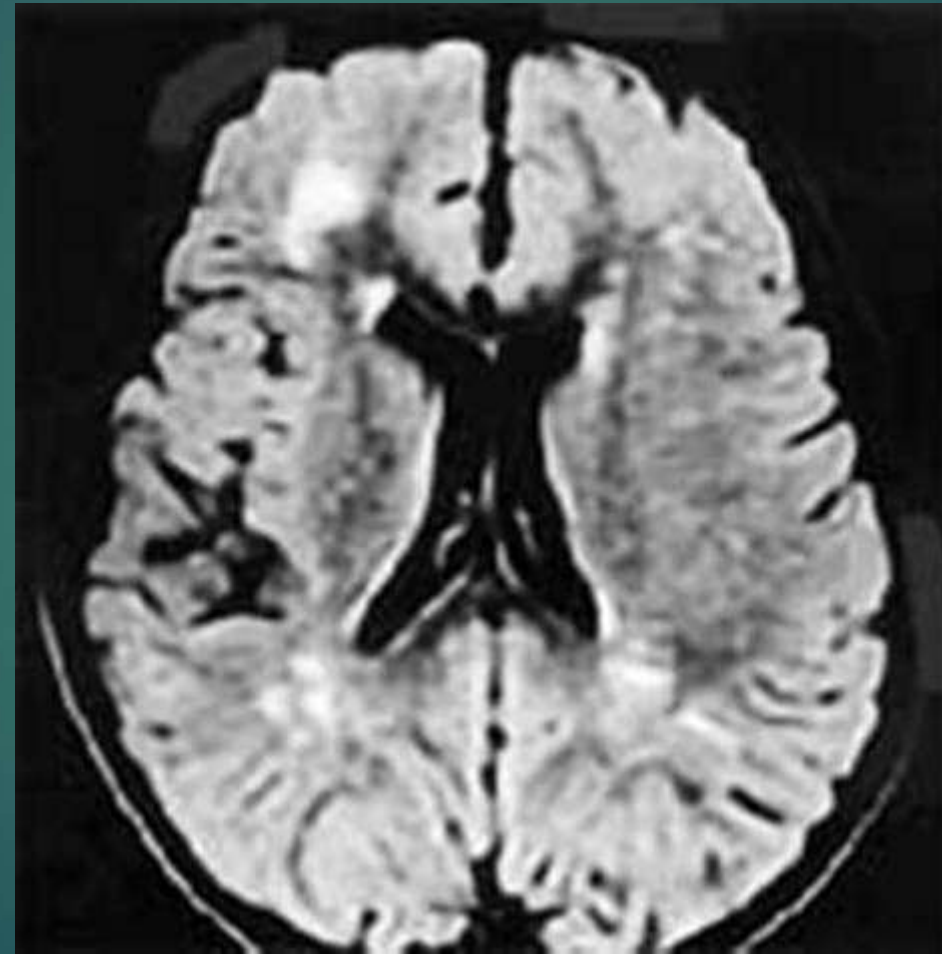
## Imaging:

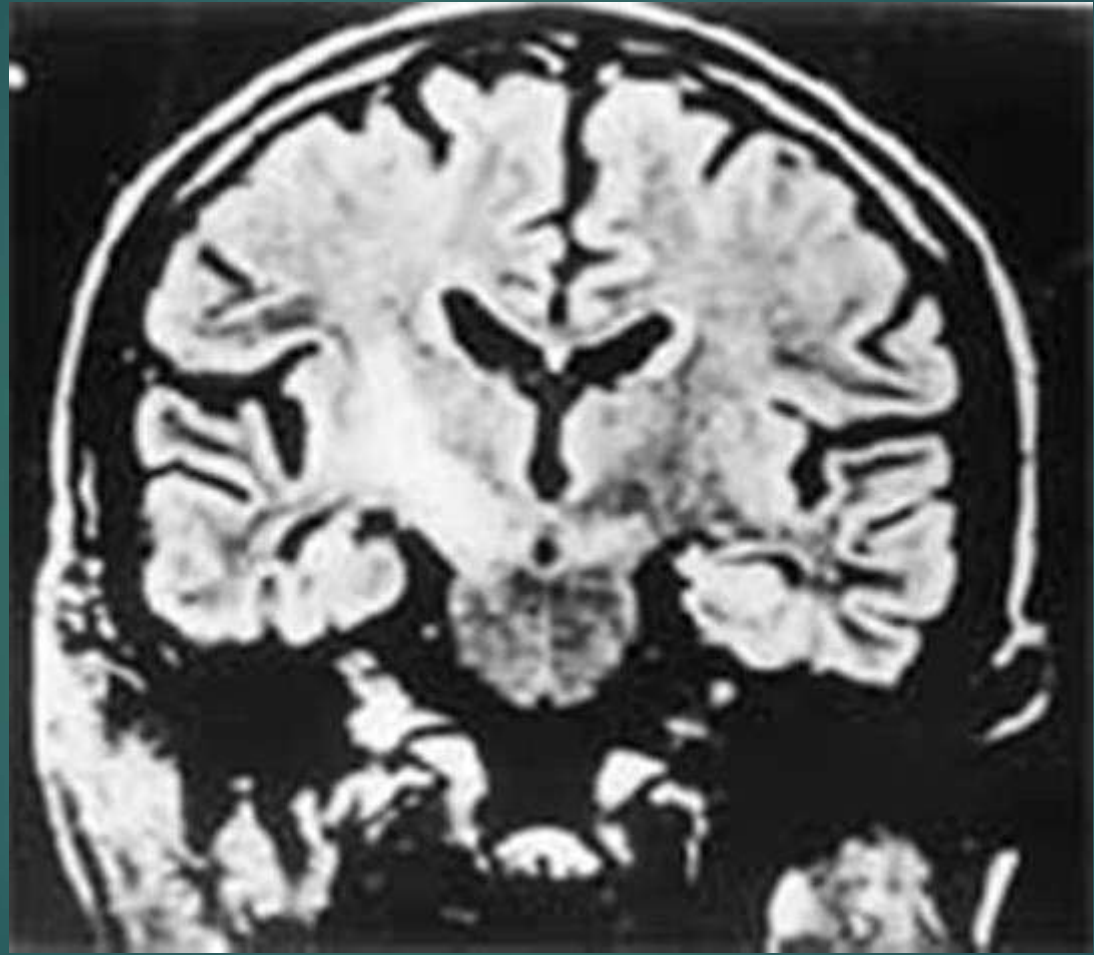
- ▶ Commonly located in the cerebral white matter (83.3%) with asymmetric and patchy involvement followed by brain stem involvement (50%).
- ▶ Spinal cord and cerebellar lesion were noted in one patient each. Thalamic involvement was seen in two cases and added to the specificity of diagnosis.

## Prognosis:

On steroid therapy, majority showed clinical improvement







# Herpes simplex encephalitis (HSE)

## Number, age and sex:

5 cases out of 40, all were females & under 20-30 years of age.

## Symptoms:

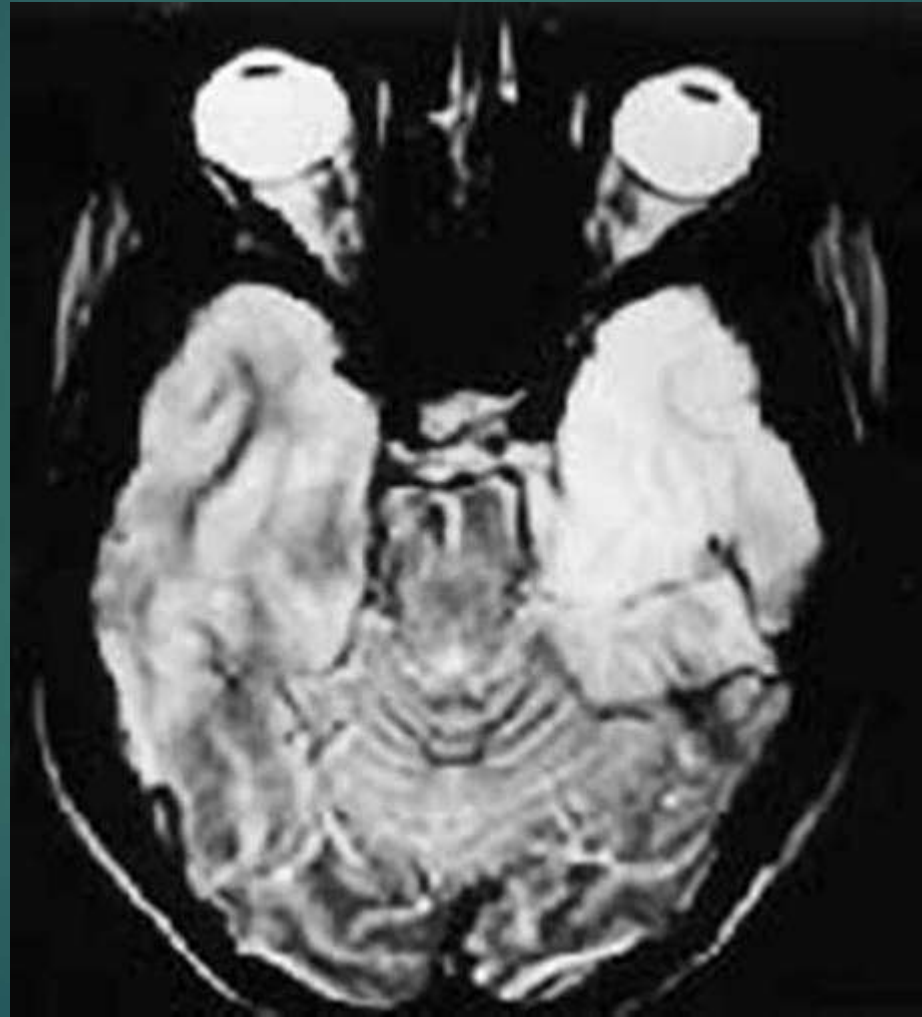
- ▶ Altered sensorium and fever (80%) followed by seizures (40%).

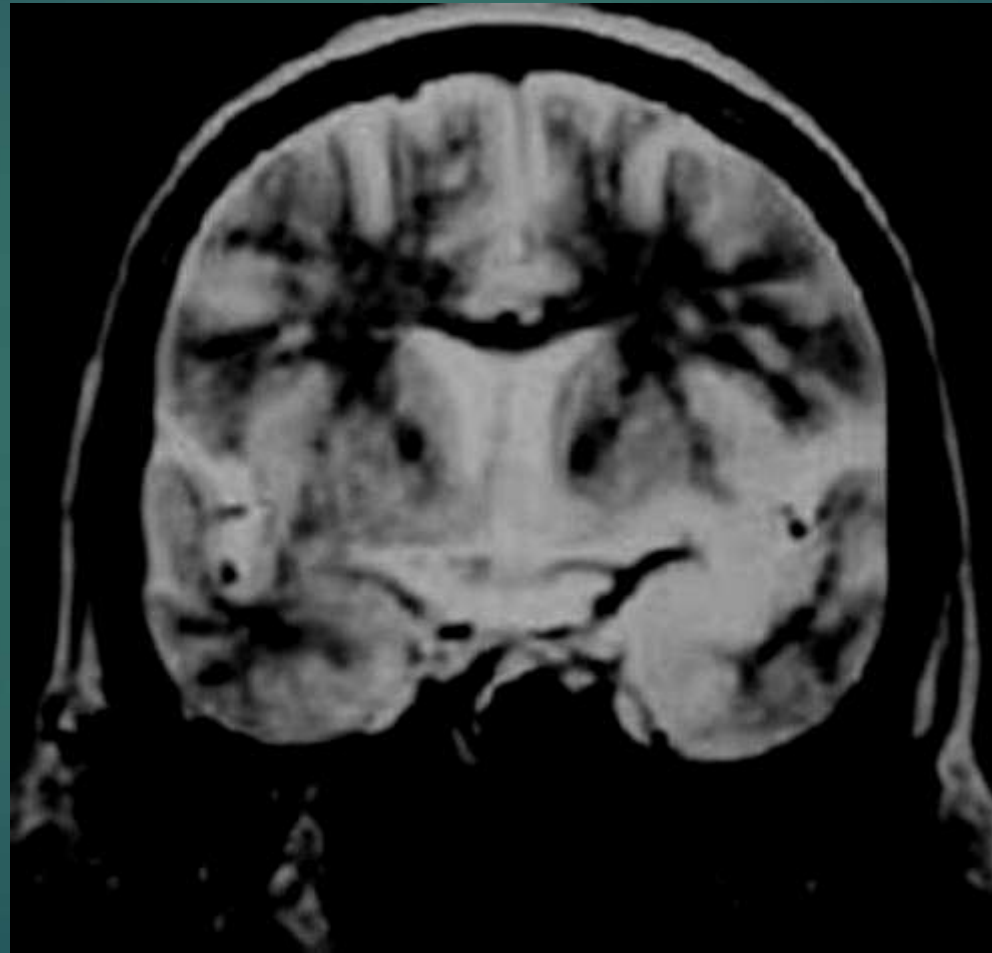
## Imaging:

- ▶ T1 hypo and T2-FLAIR hyperintensity.
- ▶ Characteristically involving the temporal lobes extending into the basifrontal areas in 60%.
- ▶ Contrast enhancement was seen in only one of the patients being patchy in appearance and hemorrhage was not noted.
- ▶ Four cases showed bilateral asymmetric involvement, the left temporal lobe being affected more than the right in 60%.
- ▶ Unilateral involvement was seen in only one case.

## Prognosis:

All cases showed prompt recovery with acyclovir therapy.





# Periventricular leucomalacia (PVL)

## Number, age & sex:

- ▶ 4 cases out of 40.
- ▶ Age range was 3 to 9 years .
- ▶ M:F= 3:1

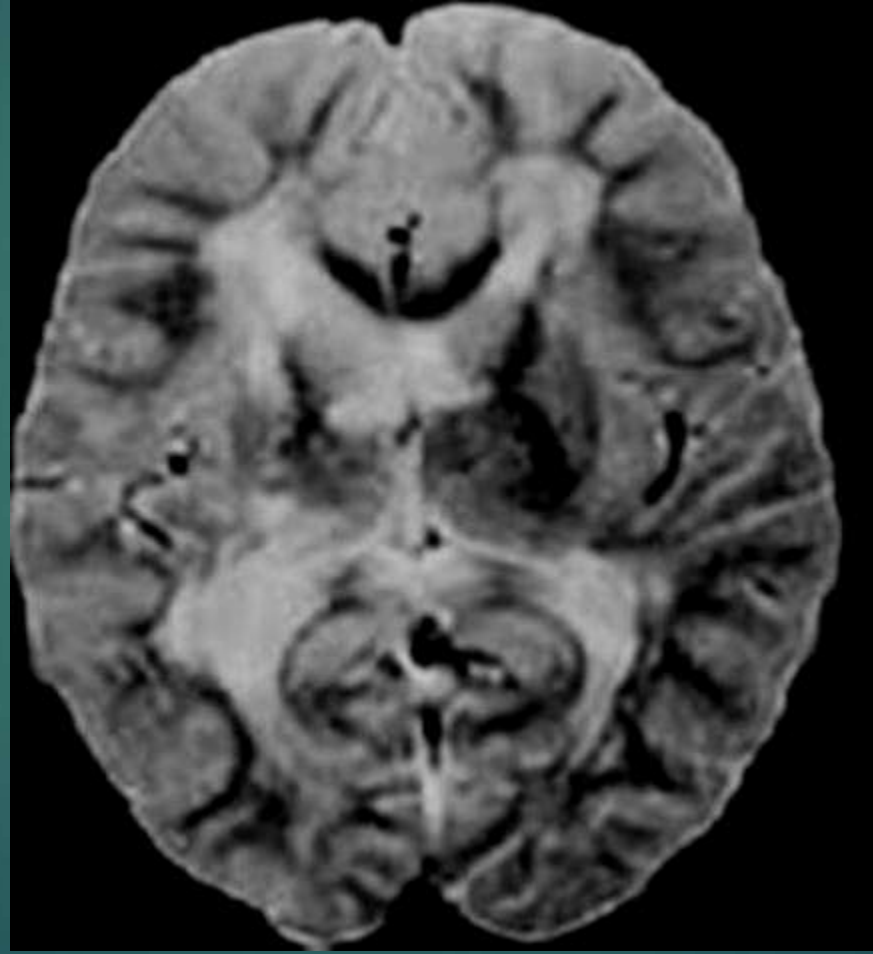
## History & clinical presentation:

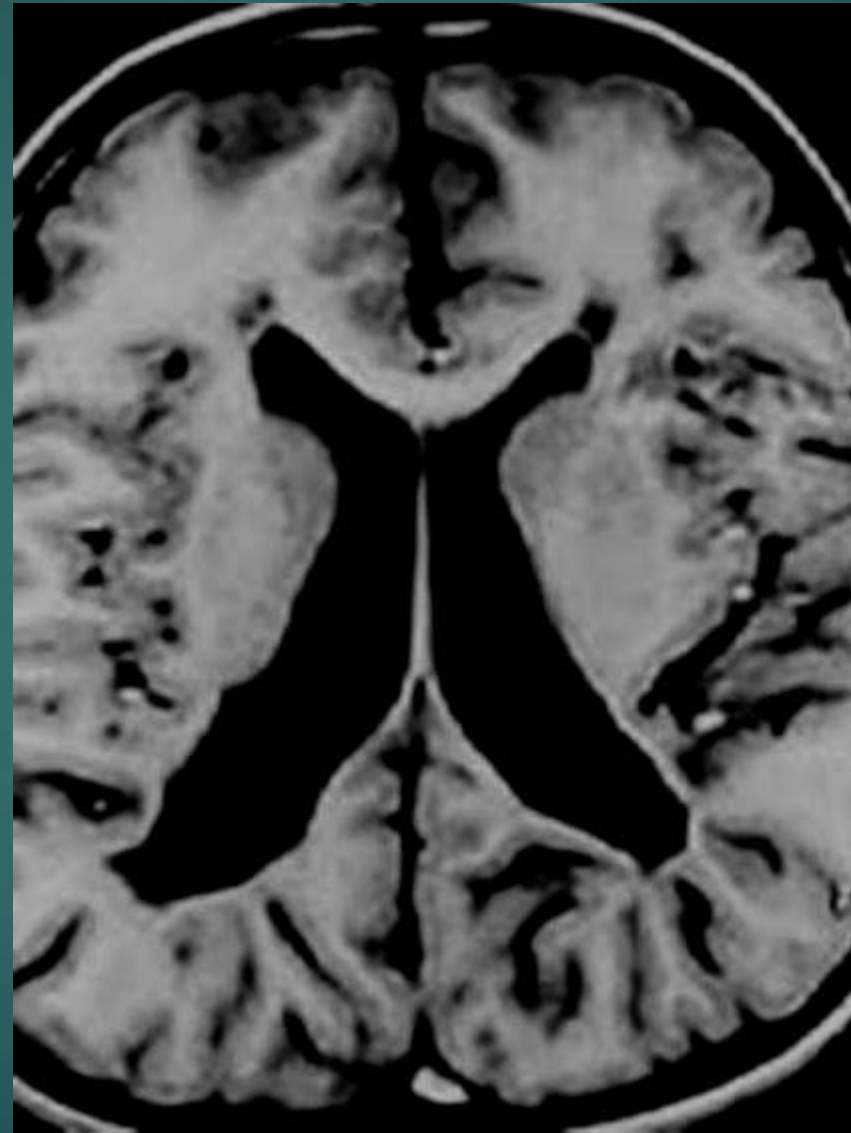
- ▶ H/O preterm delivery & asphyxia
- ▶ Full term infants with insult in the prenatal life
- ▶ Common clinical presentation was spastic diplegia (cerebral palsy) followed by seizures.

## Imaging:

- ▶ White matter volume loss and Bilateral symmetrical hyperintensity of the periventricular white matter specially of the periatrinal region in all patients.
- ▶ Ventriculomegaly and scalloping of ventricular margins







# Metachromatic Leukodystrophy (MLD)

- ▶ Two boys out of 40 cases.

## **Sign & symptoms:**

- ▶ Pyramidal dysfunction and developmental regression.

## **Imaging:**

- ▶ Bilateral symmetrical diffuse periventricular hyperintensity.
- ▶ Thalamic hypointensity on T2-weighted images and cerebral atrophy in long standing disease.

